

A case of granulomatosis with polyangiitis (GPA) initially diagnosed as limited Wegener's (LW)

Quratul Raja, MD; Julian L. Ambrus Jr., MD*

*Julian L. Ambrus Jr., MD

Division of Allergy, Immunology and Rheumatology, SUNY at Buffalo School of Medicine, Room C281, Buffalo General Hospital, 100 High Street, Buffalo, NY 14203

Tel: 716-859-2995, Fax: 716-859-1249; Email: jambrus@buffalo.edu

Abstract

We present a case in which upper and lower airway disease with a positive C-ANCA and normal urinalysis led to diagnosis of Limited Wegener's (LW). The patient was treated with corticosteroids and methotrexate with resolution of symptoms. The patient presented 9 months later in renal failure and kidney biopsy demonstrated pauci-immune crescentic glomerulonephritis with significant scarring. A diagnosis of Granulomatosis with Polyangiitis (GPA; formerly Systemic Wegener granulomatosis) was made and the patient treated with cyclophosphamide. The discussion revolves around the distinction between LW and GPA.

Keywords

limited Wegener's; granulomatosis with polyangiitis

Abbreviations

LW = limited Wegener's; GPA = Granulomatosis with Polyangiitis

Introduction

Granulomatosis with Polyangiitis (GPA) was originally called Wegener granulomatosis. It was first described by Klinger in 1931 and subsequently by Wegener in 1936 as a universally fatal disease characterized by granulomatous vasculitis in the upper and lower airways and kidneys [1,2]. In 1966, Carrington and Liebow described a limited form of Wegener's granulomatosis that involved the upper and lower airways, but not the kidneys [3]. Subsequent studies by Fauci and Wolff demonstrated, however, by doing kidney biopsies on all patients with Wegener's, that many patients felt to have limited Wegener's actually had kidney involvement [4]. Subsequent work in large numbers of patients demonstrated that patients with GPA require aggressive treatment with cyclophosphamide, while patients with LW could be treated with steroids alone or steroids and methotrexate [5]. The current case is presented because it raises the question of how to treat a patient with a clinical picture consistent with LW.

Case Presentation

RH is a 72 year old male with no significant history until the development of sinus congestion and hearing loss that did not respond to antibiotic therapy. He was seen by ENT surgery who placed tubes in both ears resulting in improved hearing. He had a chest x-ray that demonstrated multiple pulmonary

nodules. An open lung biopsy was performed because of the concern for malignancy that revealed a granulomatous vasculitis (Figure 1). He was referred to a Rheumatologist. Initial evaluation revealed WBC = 12,300, hemoglobin = 13.7 g/dL, platelets = 389,000, ESR = 52 mm/hr, CMP was completely normal including serum creatinine = 0.7mg/dL. Urinalysis was completely normal. C-ANCA = 7EhrUnit (normal <5 EhrUnit) and P-ANCA < 5 EhrUnit. A diagnosis of limited Wegener's was made and the patient placed on prednisone 60 mg daily and methotrexate 15 mg weekly with folic acid 1mg daily. The patient noted resolution of his symptoms. He has biweekly CBC, CMP and UA/micro that were normal. Prednisone was reduced to 20mg daily by the 6 months time point. At 9 months of age, the patient was off of prednisone and noted increased fatigue. CBC was normal, CMP revealed a slightly elevated serum creatinine (1.7mg/dL ; N 0.6 – 1.5 mg/dL), and urinalysis revealed 1+ protein and 3-5 rbc/hpf. A kidney biopsy was performed that revealed pauci-immune crescentic glomerulonephritis (Figure 2) with 20% obsolescent glomeruli. A diagnosis of granulomatosis with polyangiitis was made. The patient was switched from methotrexate to daily cyclophosphamide and another course of high dose prednisone was initiated.

Discussion

This case illustrates a patient in whom the conversion of LW to GPA occurred long after the patient had been successfully treated for LW. The interesting question is whether or not the patient had GPA at the onset.

Several important issues are worthy of discussion. The first is the fact that patients can have significant proliferative glomerulonephritis with a normal urinalysis. This has been documented in GPA as well as in immune complex diseases such as systemic lupus erythematosus [4,6].

The second issue is whether LW and GPA are distinct disorders or are the same disorder with different degrees of organ expression. Previous studies have demonstrated that patients with GPA have increased numbers of circulating memory B and T cells and increased numbers of memory T cells and B cells in the upper airway, lungs and kidneys [7-12]. Germinal center T cells are noted in the kidneys. In contrast, LW involves predominantly T cells and macrophages rather than B cells in lung biopsies [13]. These T cells of patients with LW produce predominantly IL-10 and interferon-g while T cells from patients with GPA were found to produce predominantly IL-4 [11,13].

The third issue is treatment. Patients with LW have been shown to respond to corticosteroids alone or to corticosteroids plus methotrexate, without the need for more aggressive therapy with cyclophosphamide [3,5,14,15]. Methotrexate is not used to induce remission in GPA, but can be used maintain remission in GPA once it is obtained, although less successfully than other agents [15-19].

Cyclophosphamide, the gold standard for the treatment of GPA eliminates all B and T cell subpopulations when given in daily doses to maintain the total WBC between 3-4,000 [5,20,21]. Monthly intravenous cyclophosphamide, which eliminates CD4 T cells, but not B cells is less effective [22,23]. The use of rituximab in GPA has achieved some success in GPA further delineating a central role for B cells in this disorder [24-28]. Significant debate exists regarding which strategies to use to induce and maintain remission in GPA, but all require elimination of B cells [27,29,30]. Neither corticosteroids nor methotrexate utilized in the treatment of LW eliminate B cells. They do both significantly inhibit

activation of macrophages[31-33].

The differential diagnosis of granulomatous inflammation in the upper and lower airways is broad [34,35]. In some cases, vasculitis may be involved. The secondary involvement of the kidney is most common in GPA, but can be seen in particular infections and drug reactions [36-38]. Appropriate therapy requires full assessment of this differential diagnosis. At the same time, however, criteria need to be developed for the specific diagnosis of LW and it should be considered as a different disorder than GPA. Diagnostic approaches need to be developed to determine which patients with granulomatous vasculitis in the upper and lower airways but normal urinalyses actually have GPA. One approach would be to do kidney biopsies on all suspected patients. This is not practical and would not be clinically indicated. Another would be to look at distribution of B and T cell subsets and macrophages along with the cytokines they are producing in lung biopsies, if these are available. Flow cytometry of lymphocyte subset in peripheral blood could also be potentially helpful, but less likely to be specific. Some strategy should be developed as the early appropriate therapy is initiated in GPA the more likely patients are to have full recovery [5,34].

Figures

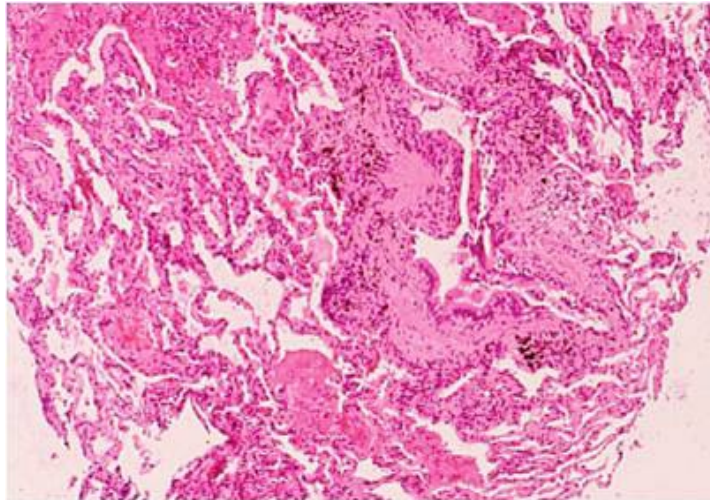


Figure 1: H&E Stain of lung biopsy

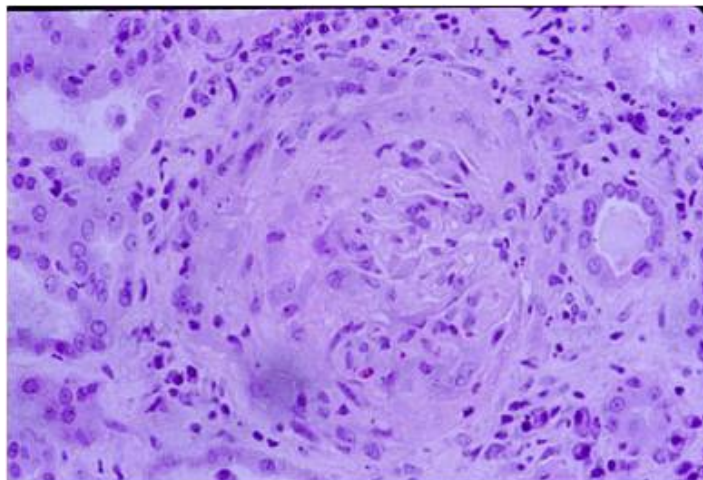


Figure 2: H&E Stain of kidney biopsy

Acknowledgements

The authors would like to thank the nurses in the Rheumatology Clinic at Buffalo General Hospital, SUNY at Buffalo School of Medicine for their help with the care of this patient.

References

1. Klinger H. Grenzformen der periarteritis nodosa. *Frankfurt Z Pathol.* 1931;42:455.
2. Wegener F. Uber generalisierte, septische Gefasser krankungen. *Verh Dtsch Ges Pathol.* 1936;29:202.
3. Carrington CB, Liebow A. Limited forms of angiitis and granulomatosis of Wegener's type. *Am J Med.* 1966;41(4):497-527.
4. Fauci AS, Wolff SM. Wegener's granulomatosis: studies in eighteen patients and a review of the literature. *Medicine (Baltimore).* 1973;52(6):535-61.
5. Hoffman GS, Kerr GS, Leavitt RY, Hallahan CW, Lebovics RS, Travis WD, et al. Wegener granulomatosis: an analysis of 158 patients [see comments]. *Ann Intern Med.* 1992;116(6):488-98.
6. Roberti I, Dikman S, Spiera H, Reisman L, Eichenfield AH, Lieberman KV. Comparative value of urinalysis, urine cytology and urine sIL2R in the assessment of renal disease in patients with systemic lupus erythematosus (SLE). *Clin Nephrol.* 1996;46(3):176-82.
7. Eriksson P, Sandell C, Backteman K, Ernerudh J. B Cell Abnormalities in Wegener's Granulomatosis and Microscopic Polyangiitis: Role of CD25+-expressing B Cells. *Journal of Rheumatology.* 2010;37(10):2086-95.
8. Voswinkel J, Mueller A, Kraemer JA, Lamprecht P, Herlyn K, HollUlrich K, et al. B lymphocyte maturation in Wegener's granulomatosis: a comparative analysis of VH genes from endonasal lesions. *Ann Rheum Dis.* 2006;65(7):859-64.
9. Wilde B, Dolff S, Cai X, Specker C, Becker J, Totsch M, et al. CD4(+)CD25(+) T-cell populations expressing CD134 and GITR are associated with disease activity in patients with Wegener's granulomatosis. *Nephrology Dialysis Transplantation.* 2009;24(1):161-71.
10. Abdulahad WH, vanderGeld YM, Stegeman CA, Kallenberg CGM. Persistent expansion of CD4(+) effector memory T cells in Wegener's granulomatosis. *Kidney international.* 2006;70(5):938-47.
11. Balding CEJ, Howie AJ, DrakeLee AB, Savage COS. Th2 dominance in nasal mucosa in patients with Wegener's granulomatosis. *Clin Exp Immunol.* 2001;125(2):332-9.
12. CoulombLHermine A, Capron F, Zou WP, Piard F, Galateau F, Laurent P, et al. Expression of the chemokine RANTES in pulmonary Wegener's granulomatosis. *Hum Pathol.* 2001;32(3):320-6.
13. Muller A, Trabandt A, GloecknerHofmann K, Seitzer U, Csernok E, Schonermarck U, et al. Localized Wegener's granulomatosis: Predominance of CD26 and IFN-gamma expression. *J Pathol.* 2000;192(1):113-20.
14. Stavrou J. Ocular manifestations of classical and limited Wegener's granulomatosis. *QuatJMed.* 1993;86:719-25.
15. Hoffman GS, Leavitt RY, Kerr GS, Fauci AS. The treatment of Wegener's granulomatosis with glucocorticoids and methotrexate. *Arthritis and rheumatism.* 1992;35(11):1322-9.
16. DeGroot K, Muhler M, ReinholdKeller E, Paulsen J, Gross WL. Induction of remission in Wegener's granulomatosis with low dose methotrexate. *The Journal of rheumatology.* 1998;25(3):492-5.
17. deGroot K, Rasmussen N, Bacon PA, Tervaert JWC, Feighery C, Gregorini G, et al. Randomized trial of cyclophosphamide versus methotrexate for induction of remission in early systemic antineutrophil cytoplasmic antibody-associated vasculitis. *Arthritis and rheumatism.* 2005;52(8):2461-9.

18. Langford CA, TalarWilliams C, Barron KS, Sneller MC. Use of a cyclophosphamide-induction methotrexate-maintenance regimen for the treatment of Wegener's granulomatosis: Extended follow-up and rate of relapse. *Amer J Med.* 2003;114(6):463-9.
19. Villa-Forte A, Clark TM, Gomes M, Carey J, Mascha E, Karafa MT, et al. Substitution of methotrexate for cyclophosphamide in Wegener granulomatosis: a 12-year single-practice experience. *Medicine (Baltimore).* 2007;86(5):269-77.
20. Holle JU, Gross WL, Latza U, Nolle B, Ambrosch P, Heller M, et al. Improved Outcome in 445 Patients With Wegener's Granulomatosis in a German Vasculitis Center Over Four Decades. *Arthritis and rheumatism.* 2011;63(1):257-66.
21. Cupps TR, Edgar LC, Fauci AS. Suppression of human B lymphocyte function by cyclophosphamide. *Journal of immunology.* 1982;128(6):2453-7.
22. de Groot K, Harper L, Jayne DRW, Suarez LFF, Gregorini G, Gross WL, et al. Pulse Versus Daily Oral Cyclophosphamide for Induction of Remission in Antineutrophil Cytoplasmic Antibody-Associated Vasculitis A Randomized Trial. *Annals of Internal Medicine.* 2009;150(10):670-U3.
23. Hoffman GS, Leavitt RY, Fleisher TA, Minor JR, Fauci AS. Treatment of Wegener's granulomatosis with intermittent high-dose intravenous cyclophosphamide. *Am J Med.* 1990;89(4):403-10.
24. Roubaud-Baudron C, Pagnoux C, Meaux-Ruault N, Grasland A, Zoulim A, Le Guen J, et al. Rituximab Maintenance Therapy for Granulomatosis with Polyangiitis and Microscopic Polyangiitis. *Journal of Rheumatology.* 2012;39(1):125-30.
25. Stone JH, Merkel PA, Spiera R, Seo P, Langford CA, Hoffman GS, et al. Rituximab versus cyclophosphamide for ANCA-associated vasculitis. *The New England journal of medicine.* 2010;363(3):221-32.
26. Silva-Fernandez L, Loza E, Martinez-Taboada VM, Blanco R, Rua-Figueroa I, Pego-Reigosa JM, et al. Biological therapy for systemic vasculitis: A systematic review. *Seminars in Arthritis and Rheumatism.* 2014;43(4):542-57.
27. Henderson SR, Copley SJ, Pusey CD, Ind PW, Salama AD. Prolonged B Cell Depletion With Rituximab is Effective in Treating Refractory Pulmonary Granulomatous Inflammation in Granulomatosis With Polyangiitis (GPA). *Medicine.* 2014;93(27).
28. Vishwanath S, Relan M, Shen L, Ambrus JL. Update on the Use of Biologics in Vasculitides. *Current Pharmaceutical Biotechnology.* 2014;15(6):558-62.
29. Puechal X, Pagnoux C, Perrodeau E, Hamidou M, Boffa JJ, Kyndt X, et al. Long-Term Outcomes Among Participants in the WEGENT Trial of Remission-Maintenance Therapy for Granulomatosis With Polyangiitis (Wegener's) or Microscopic Polyangiitis. *Arthritis & Rheumatology.* 2016;68(3):690-701.
30. Sada KE, Yamamura M, Harigai M, Fujii T, Takasaki Y, Amano K, et al. Different responses to treatment across classified diseases and severities in Japanese patients with microscopic polyangiitis and granulomatosis with polyangiitis: a nationwide prospective inception cohort study. *Arthritis Research & Therapy.* 2015;17.
31. Neurath MF, Hildner K, Becker C, Schlaak JF, Barbulescu K, Germann T, et al. Methotrexate specifically modulates cytokine production by T cells and macrophages in murine collagen-induced arthritis (CIA): a mechanism for methotrexate-mediated immunosuppression. *Clin Exp Immunol.* 1999;115(1):42-55.
32. Bondeson J. The mechanisms of action of disease-modifying antirheumatic drugs: a review with emphasis on macrophage signal transduction and the induction of proinflammatory cytokines. *Gen Pharmacol.* 1997;29(2):127-50.
33. Zen M, Canova M, Campana C, Bettio S, Nalotto L, Rampudda M, et al. The kaleidoscope of glucocorticoid effects on immune system. *Autoimmunity Reviews.* 2011;10(6):305-10.