

Olmesartan associated enteropathy and colopathy. Is this a pan GI disorder?

Hamid Yousuf*; Padraic MacMathuna

*Hamid Yousuf

Department of Gastroenterology, Mater University Hospital Dublin, Ireland

Email: drhamids@hotmail.com

Abstract

Introduction: Olmesartan medoxomil is an Angiotensin II Receptor Blocker (ARB) for the treatment of high blood pressure. Olmesartan Induced Enteropathy (OIE) is rare entity and difficult to distinguish from coeliac sprue and auto immune enteropathy.

We present as case of severe OIE in a 64-year-old Irish lady taking Olmesartan for 3 years. She presented to a local hospital with diarrhea, significant vomiting and weight loss. Conventional treatment failed to cure symptoms. All basic and advance investigations including CT abdomen Pelvis and MR Enterography were normal. Anti TTG was normal with normal IgA. Eventually transferred to tertiary care hospital for further investigation and management. Showed dramatic response as soon as Olmesartan has been stopped on arrival. Mean while a gastro duodenoscopy with duodenal biopsy showed severe blunting of villi consistent with OIE. Repeat endoscopy few months later showed normal villous architecture with complete resolutions of symptoms.

Most patients present with non-bloody diarrhea, weight loss along with other common symptoms like nausea, vomiting and abdominal pain. Our case is different as predominant clinical problem was intractable vomiting and weight loss.

Conclusion: OIE is a rare and potential life threatening, but easily treatable condition. Physicians keep their differentials broad and should consider Angiotensin receptor blockers as potential etiologies of enteropathy.

Keywords

olmesartan; villous atrophy; enteropathy; coeliac sprue

Introduction

Olmesartan medoxomil is one of eight marketed Angiotensin II Receptor Blocker (ARB) for the treatment of high blood pressure [1]. It was approved in 2002 in the USA, and in 2003 in the European Union, for the treatment of hypertension. In a phase 3 ROADMAP trial, performed in 4447 patients with diabetes mellitus, the incidence of diarrhea and abdominal discomfort were similar in the Olmesartan and the placebo group [2,3].

Patients with Olmesartan-Induced Enteropathy (OIE) typically present with diarrhoea, weight loss, and nausea. Vomiting is relatively less common [4]. OIE is rare and may be difficult to recognize because of its clinical and histologic similarities to coeliac sprue and autoimmune enteropathy but can be distinguished from celiac disease by the absence of positive celiac serology. OIE affects both men and women equally. Mean age of onset is 68 years (range 46–91 years) [5].

Case Summary

A 64-year-old Irish lady presented to a regional hospital with a 5-day history of significant vomiting and diarrhoea. Background medical history included Type 1 Diabetes Mellitus, achalasia, hypertension, and a history of recurrent diarrhoea. Socially, she was a non-smoker, drinks alcohol in moderation (2-3 units per week). She denied any symptoms suggestive of local or systemic infection, recent travel, sick contacts, or changes in her diet or medications. She reported an allergy to trimethoprim.

The clinical features were a 5-day history of severe vomiting with associated profuse non-bloody diarrhoea of a paste-like consistency. Initially, the presumptive diagnosis was gastroenteritis or diabetic gastro-enteropathy, but treatment with anti-emetics and anti-motility agents was unsuccessful.

Initial blood investigations were unremarkable, with normal white cell count (WCC) and a mildly elevated and fluctuating C-reactive protein (CRP) of between 10-20 mg/L, which normalised spontaneously. Sigmoidoscopy performed in 2 weeks post admission was normal, this is followed by CT abdomen and pelvis with unremarkable findings. An Oesophago-gastro- duodenoscopy (OGD) was performed week later, which was normal as well. Of note, duodenal biopsies were not performed at this stage. Later an MR Enterography did not show any enteropathy. Other investigations for possible underlying causes for the patient's constellation of symptoms, including autoantibody screen, anti- Tissue Transglutaminase (TTG) antibodies, Thyroid Function Tests (TFTs), Serum Protein Electrophoresis (SPEP), and screen for causes of infectious colitis (including Salmonella, Shigella, Campylobacter, Vero toxigenic E. coli, Clostridium difficile, S. typhus and S. Para typhus) were all negative. A 24- hour urinary collection for 5-HIAA was also normal.

Nausea and vomiting persisted and lead to significant weight loss, meanwhile patient failed trial of NG feeding due to significant vomiting, so Total Parenteral Nutrition (TPN) was commenced after 3 weeks of admission. She continued to lose a significant amount of weight and failed to respond to trials of cholestyramine and pancreatic enzyme replacement.

Due to lack of symptoms control after 5 weeks of hospital admission, a transfer to tertiary care university hospital has been arranged for further investigation and management. On admission, her medications included enoxaparin subcutaneous, ondansetron, aspirin, rosuvastatin, mirabegron, thiamine, Creon, Olmesartan. The insulin regime included Lantus pre-breakfast and Novo rapid pre-meals. Physical examination was normal. It was decided to stop oral medications including Olmesartan which was considered a potential 'culprit' underlying the refractory diarrhoea. Of interest, the patient had been on Olmesartan continuously since November 2014.

Her TPN was continued. Within 48 hours, she underwent repeat OGD (with duodenal biopsies) and full colonoscopy to the terminal ileum with biopsies.

Within 2 day, the patient's symptoms resolved dramatically. The vomiting stopped and the diarrhoea significantly improved with reduced in frequency and increased consistency. Duodenal biopsy demonstrated acute duodenitis and marked villous flattening features consistent with OIE. Biopsies taken during ilio-colonoscopy showed marked acute ileitis with cryptitis and moderate to severe acute colitis with focal cryptitis and crypt abscess in the right and left colon.

Olmesartan was permanently discontinued. Her other medications were re-instated gradually. The patient continued to improve and gradually began to tolerate oral feeding. Vomiting and diarrhoea completely resolved. The patient was discharged 10 days after admission in tertiary care hospital.

At follow-up clinic visits (4 and 12 weeks after discharge), she was asymptomatic having regained most of the weight lost. Repeat duodenal histology after 10 weeks demonstrated normal small bowel mucosa.

Discussion

Our case illustrates a case of severe OIE and subsequent rapid and remarkable clinical improvement following suspension of Olmesartan therapy. Small bowel biopsy confirmed moderately severe acute enteropathy including villous blunting. Celiac disease was excluded by negative conventional serology tests. Our patient presented with a constellation of clinical symptoms, endoscopy findings, and histological features consistent with the clinicopathological spectrum of OIE reported in the literature. However, the dominance of vomiting and involvement of ilio-colonic mucosa is bit unusual.

Most patients with OIE present with chronic, non-bloody diarrhoea and weight loss. Other commonly reported symptoms include fatigue, nausea, vomiting, abdominal pain, and bloating. Our case is different that intractable vomiting with weight loss was predominant clinical problem, and best of our knowledge vomiting is not prominent clinical manifestation of OIE in previous published reports. Patients typically develop symptoms months to years after initiation of Olmesartan therapy ^[5], and same in our case 3 years after starting treatment.

Rubio-Tapia et al were the first that initially highlighted an association between Olmesartan therapy and enteropathy in a series of 22 patients (median age 69.5 years) who presented with severe diarrhea

and weight loss. Most patients had been taking Olmesartan daily for mean duration of 3.1 years before developing symptoms. Clinical improvement was observed in all patients after suspension of Olmesartan. In all patients, IgA anti-TTG antibodies were negative. Intestinal biopsies demonstrated villous atrophy in all patients [4]. Several other case reports and series have reported similar findings.

In a series of 72 adult patients with non-celiac enteropathy and villous atrophy, De Gaetani *et al* reported 16 patients with OIE and 15/16 patients improved after Olmesartan withdrawal [6].

In 2013, these reports have led the United States Food and Drug Administration (FDA) issued a 'Drug Safety Communication' approving a label change to include sprue-like enteropathy linked to Olmesartan [1].

The largest experience of OIE originates from a large nationwide French observational patient cohort of 4,546,680 patients who initiated therapy with Olmesartan, or a different ARB, or an ACE inhibitor [7].

Another case series of five patients with Olmesartan associated sprue like enteropathy reported diarrhoea and weight loss were dominant symptoms [8].

More recently two cases reported by Galanopoulos *et al* with predominant symptoms of non-bloody diarrhoea and weight loss. Vomiting was not reported in either case [9].

Another distinguishing feature of our case was evidence of acute significant ileitis and colitis on biopsies taken during ilio-colonoscopy. Though collagenous colitis was mentioned in very few published OIE cases but from our literature review acute colitis is not a well appreciated feature. A report of 3 cases demonstrated chronic inflammation of colon and prominent lymphocytosis suggestive of lymphocytic colitis but not chronic inflammatory disease [10].

In another French study, 36 people with Olmesartan-associated enteropathy were reported. They described endoscopic appearance of jejunum or ileum for 17 patients either by capsule endoscopy or by ilio-colonoscopy. 47% has a normal small bowel, 35% had atrophic (35%) and 12% had jejunal and/or ileal ulcerations. Lymphocytic colitis was found in four patients [11].

In an effort to determine if literature was emphasizing an exceedingly rare reaction to Olmesartan or the most severe cases in a clinical spectrum of OIE a case-control study of 2,088 patients undergoing OGD and 12,428 patients undergoing colonoscopy was performed. Results showed that Olmesartan was not associated with diarrhea among patients undergoing endoscopy. There was no association seen between the use of Olmesartan and the histologic diagnosis of celiac disease or microscopic colitis respectively, suggesting that Olmesartan-associated enteropathy is not part of a broader disease spectrum [12].

In view of the long latency period between the initiation of Olmesartan and the development of symptoms, it is unlikely that OIE is the result of a type I hypersensitivity response. The mechanism underlying the Small bowel tissue damage is unclear but may involve angiotensin II induced enhanced gene expression of transforming growth factor- β (TGF- β), which is involved in damage to various organs [13].

Microscopic findings

Pictures showing Olmesartan induced villous atrophy and subsequent full recovery on withdrawal in our patient case.

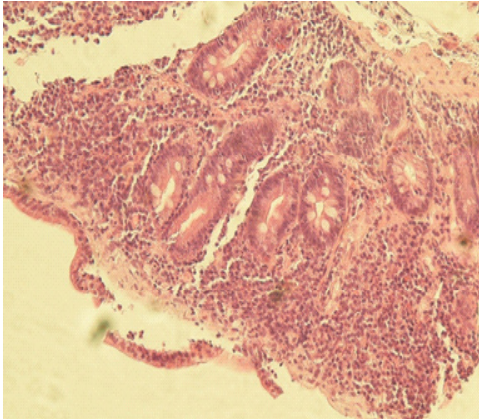


Figure 1: OIE. Duodenum biopsy showing flattening/absence of villi.

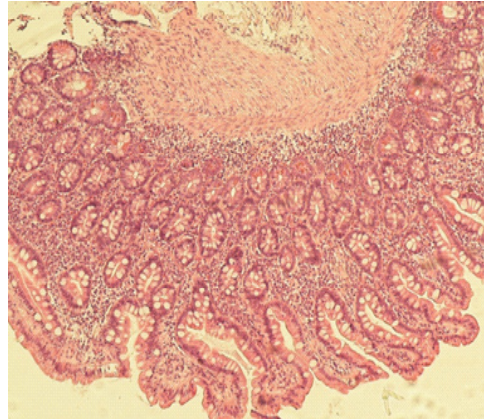


Figure 2: Post Olmesartan withdrawal recovery. Duodenal biopsy showing normal villous architecture.

Conclusion

Though it's a rare entity that Olmesartan causes severe life-threatening enteropathy. This case was unique as our patient presented with intractable vomiting which dominated the clinical picture (in addition to severe diarrhea). She achieved rapid clinical improvement within a very short period of time following discontinuation of the drug. In the assessment of enteropathy, physicians should be mindful of the broad differential diagnosis including medications, particularly Olmesartan.

References

1. <http://www.fda.gov/Drugs/DrugSafety/ucm359477.html>.
2. Haller H, Ito S, Izzo JL, Januszewicz A, Katayama S, Menne J, et al. Olmesartan for the delay or prevention of microalbuminuria in type 2 diabetes. *N Engl J Med*. 2011; 364: 907-917.
3. Menne J, Haller H. Olmesartan and intestinal adverse effects in the ROADMAP study. *Mayo Clin Proc*. 2012; 87: 1230–1231.
4. Rubio-Tapia A, Herman ML, Ludvigsson JF, Kelly DG, Mangan TF, Wu TT, et al. Severe spruelike enteropathy associated with olmesartan. *Mayo Clin Proc*. 2012; 87: 732-8.
5. Ianiro G, Bibbo S, Montalto M, Ricci R, Gasbarrini A, Cammarota G. Systematic review: sprue-like enteropathy associated with olmesartan. *Aliment Pharmacol Ther*. 2014; 40: 16–23.
6. De Gaetani M, Tennyson CA, Lebwohl B, Lewis SK, Abu Daya H, Arguelles-Grande C, et al. Villous atrophy and negative celiac serology: a diagnostic and therapeutic dilemma. *Am J Gastroenterol*. 2013; 108: 647-653.
7. Basson M, Mezzarobba M, Weill A, Ricordeau P, Allemand H, Alla F, et al. Severe intestinal malabsorption associated with olmesartan: a French nationwide observational cohort study. *Gut*. 2016; 65: 1664-1669.
8. Théophile H, David XR, Miremont-Salamé G, Haramburu F. Five cases of sprue-like enteropathy in patients treated by olmesartan. *Dig Liver Dis* 2014; 46: 465-469.
9. Galanopoulos M, Varytimiadis L, Tsigaridas A, Karatzas PS, Archavlis E, Viazis N, et al. Small bowel enteropathy associated with olmesartan medoxomil treatment. *Ann Gastroenterol*. 2017; 30: 131-133.
10. Adike Ab, Corral Ju, Rybnicek Da, Sussman Da, Shah Sa, Quigley Ea, et al. Olmesartan-Induced Enteropathy. *Methodist*