

## Parotid gland lipoma

Cristina Monteiro\*; Bruno Ribeiro da Silva; Alberto Midões

\*Cristina Monteiro

General Surgery of Local Health Unit of Alto Minho - Santa Luzia Hospital, Santa Luzia Road, Rua Arquitecto André Soares, 92 - Block 1A H05 4935-165, Viana do Castelo, Portugal

### Image Description

The authors present a case of a 39-year-old caucasian patient referred to our Department with a right facial mass. The patient's main complaint was aesthetics. He had no pain but reported that the mass had been slowly growing for three years. Clinical examination confirmed a mobile, soft and smooth right mandibular mass with 50 mm of major diameter. Function of the facial nerve was intact.

He underwent a CT scan that showed the presence of a right parotid mass measuring 50x34x30 mm (Figure 1, 2), with internal septa and a fat-like structure, compatible with a Lipoma of the Parotid Gland.

We performed a Partial Parotidectomy under general anesthesia. The specimen was regular shaped and measured 55x35 mm.

The histological report revealed an adipose tissue node without atypia, confirming the suspected diagnosis: Intra Parotid Lipoma.

Although Lipomas are a common benign mesenchymal tumor, Parotid Gland Lipomas are rare entities. Nonetheless, they may be always considered in the differential diagnosis of these Gland tumors. The excision biopsy is the final and effective treatment.

### Figures

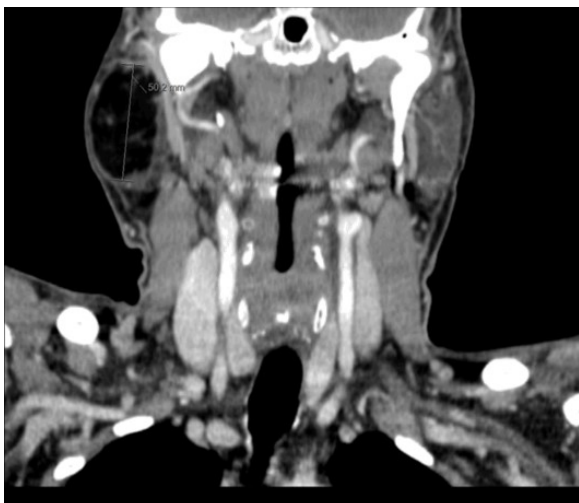

Figure 1: CT scan - Right Parotid Gland Lipoma

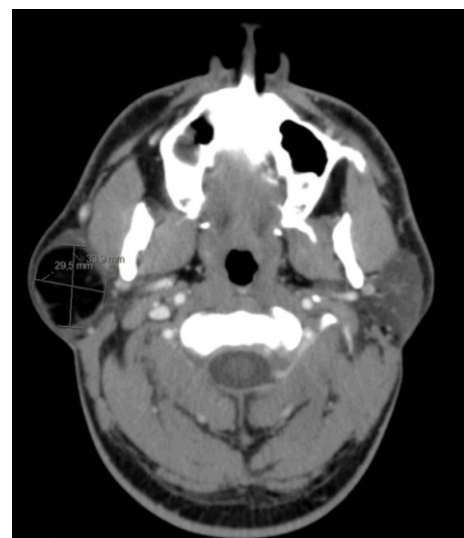


Figure 2: CT scan - Right Parotid Gland Lipoma