

Natural killer cell leukemia: A rare case

Maryam Zulfiqar*; Bushra Anam Ali; Asma Mustafa; Lubna Naseem

*Maryam Zulfiqar

Department of Pathology, Pakistan Institute of Medical Sciences, Islamabad

Abstract

Aggressive natural killer cell leukemia/lymphoma is a rare and highly aggressive NK cell neoplasm with a short clinical course and poor prognosis, which is almost always EBV related. It often affects young patients and is characterized by relative resistance to standard chemotherapy. Here we report a case of 62 years old male who presented to us with complaints of fever, constipation, and generalized body aches for the past one week. His diagnosis of NK cell leukemia was made on having characteristic cells on peripheral film and with the help of flow cytometry.

Keywords

bone marrow; immunohistochemistry; natural killer cells; CD56

Case Report

A 62 year male known case of hypertension, presented in the medical emergency with the complaints of fever, generalized body weakness, constipation and shortness of breath for the past one week. Fever was continuous and high grade with no history of nausea, vomiting or bony tenderness.

Physical examination: Patient was pale looking, lethargic and well oriented. There was mild abdominal distention noted. All other physical findings e.g. jaundice, posture, nail clubbing, palmar erythema, pigmentation contractures, hairs, lymph nodes, and were found unremarkable.

Systemic examination: Cardiovascular, pulmonary, central nervous and musculoskeletal systems were normal. However, on examination of alimentary system there was abdominal distention with enlarged spleen almost 6cm below left costal margin and liver being palpable 2cm below right costal margin.

Laboratory Findings

Table 1: shows laboratory findings of complete blood picture.

Sr. No.	Blood CP Parameters	Value	Normal Range
1	Hemoglobin	8.7g/dl	14-18 g/dl
2	Red Cell Count	3.46×10^6 uL	4.1-6.1x106uL
3	White Cell Count	12.1×10^3 /uL	4.0-11.0x103/uL
4	Hematocrit	25.3%	30-40%

5	Platelet Count	50x1000/UL	150-450X1000/UL
6	Reticulocyte Count	0.3%	0.1-4.0 %
7	Erythrocyte sedimentation rate (ESR)	15mm	0-20 mm

On peripheral smear hypochromic microcytic picture with mild anisocytosis and few target cells were present. Platelets were decreased with giant platelets seen. There was marked leukocytosis on peripheral film with an absolute neutrophil count of 7600/ml. There were large lymphocytes having atypical nuclei, irregular folding's and open chromatin with prominent nucleoli in some. There is basophilic cytoplasm with coarse azurophilic granules (figure 1).

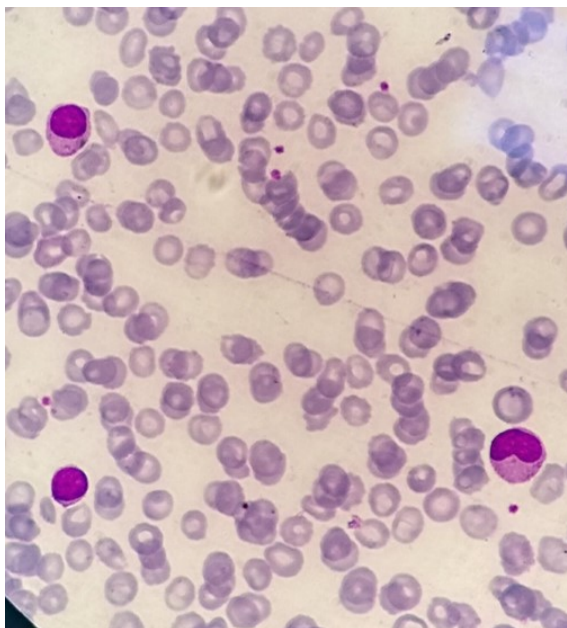


Figure 1: shows two large lymphocytes with basophilic cytoplasm and coarse granules, as compared to a normal lymphocyte in the left corner.

Table 2: shows routine biochemical laboratory tests along with coagulation profile.

Sr. No.	Parameters	Value	Normal Range
Liver function Tests			
1	Alkaline Phosphatase	126 IU/L	115-460 IU/L
2	Alkaline Tranferase	163 IU/L	0-30 IU/L
3	Bilirubin	1.58 mg/dl	<0.1 mg/dl
RFTs			
4	Urea	35 mg/dl	40-180 mg/dl
5	Creatinine	10 mg/dl	25-125 mg/dL
Hepatitis screening			35-82 mg/dl
6	Hbs Ag	NEGATIVE	
7	Anti HCV	NEGATIVE	

Electrolytes			
8	Calcium	0.97mmol/L	2.2-2.7mmol/L
9	Sodium	122 m Eq/L	135-147mmol/L
10	Potassium	2.9 m mol/L	3.5-5.5 m mol/L
Others			
11	Blood Sugar Random	139mg/dl	100-180mg/dl
12	LDH	2535 U/L	140 - 280 U/L
13	Dengue serology	Negative	
14	ICT MP	Negative	
Coagulation Profile			
15	Pro thrombin Time	13 sec	12 sec
16	Activated Partial thrombin Time	32 sec	32 sec
17	International Normalized Ratio (INR)	0.94	1.0
18	Bleeding Time	5min	2-5 min

Radiological Findings: On ultrasound abdomen there was moderate hepatosplenomegaly noted.

Immuno-phenotyping: immune phenotyping was performed on peripheral blood sample for acute leukemia's which showed CD45: 99%, CD5,CD20,CD23,CD19,CD22,CD10,CD3,CD14, CD19+38, CD117 (0%), HLA DR(15%), CD38 (98%), CD16+56 (93%), suggestive of NK cell leukemia.

Bone marrow aspirate findings: Bone marrow was performed through posterior superior iliac spine which showed hyper cellular marrow with moderate erythroid series which was normoblastic with mild dyserythropoiesis. Myeloid series was hyperplastic with both mature and early granulocytic precursors present. Megakaryocytes were adequate with normal maturation. Histiocytes were prominent with hemophagocytosis. Lymphocytes were also prominent on smear. There were cells (10%) with atypical nuclei, irregular folding's and open chromatin with prominent nucleoli in some (Figure 2). There is basophilic cytoplasm with coarse azurophilic granules.

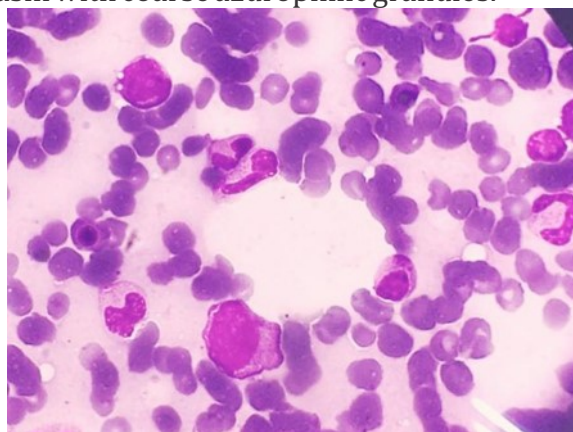


Figure 2: shows atypical cells with irregular margins and basophilic cytoplasm.

Bone marrow trephine biopsy: it showed hyper cellular marrow with moderate distribution of erythroid and myeloid series, megakaryocytes were depressed and there were prominent lymphocytes. There was interstitial infiltration by atypical mononuclear cells in the sections examined. Immunohistochemistry was performed on trephine, which showed a strong CD56 with negative CD3, CD5, CD20 and CD23, indicative of aggressive natural killer cell leukemia

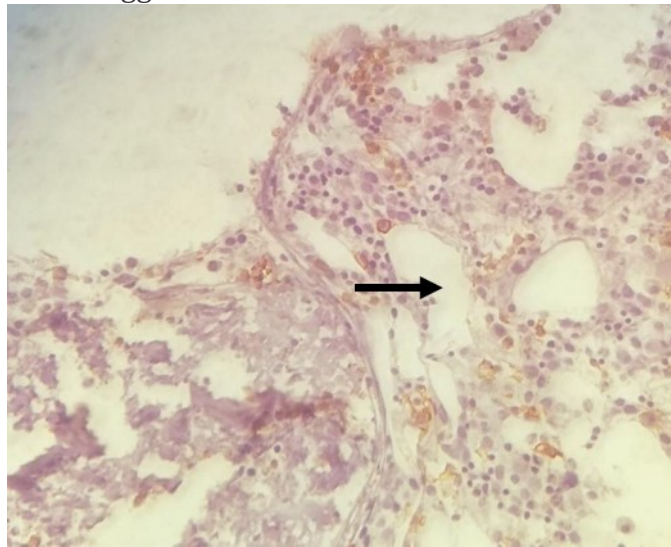


Figure 3: atypical cells on trephine showing positivity for CD56 on immunohistochemistry.

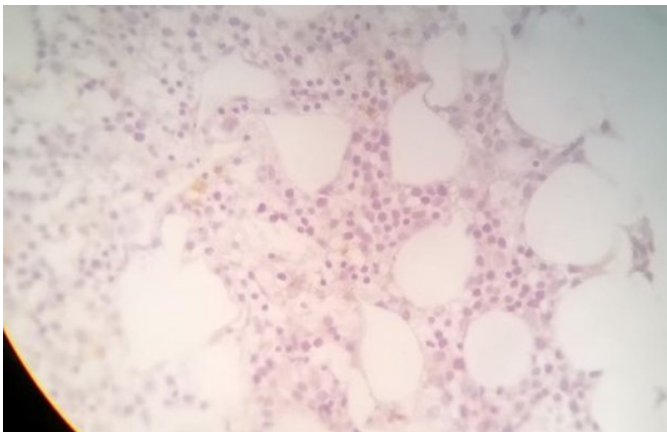


Figure 4: cells shows negativity for CD3 marker

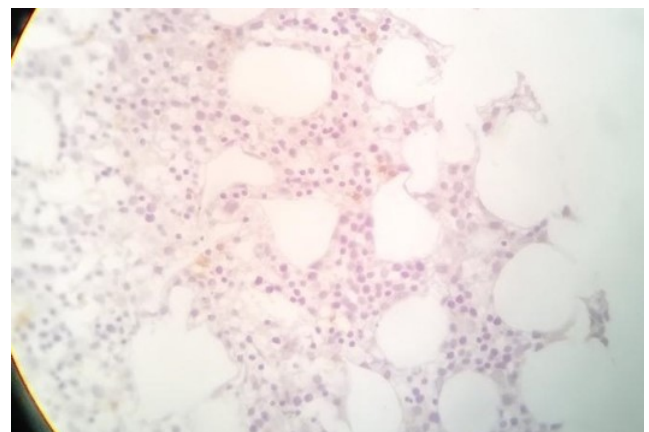


Figure 5: cells shows negativity for CD5 marker

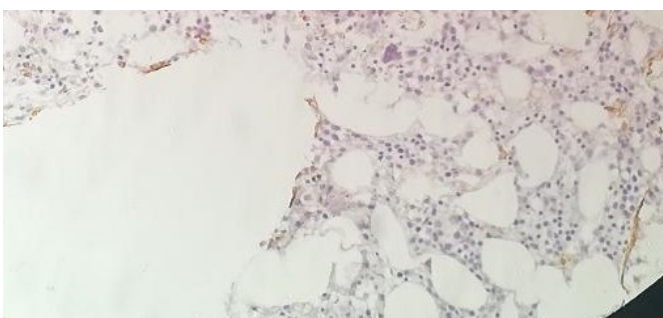


Figure 6: cells shows negativity for CD23

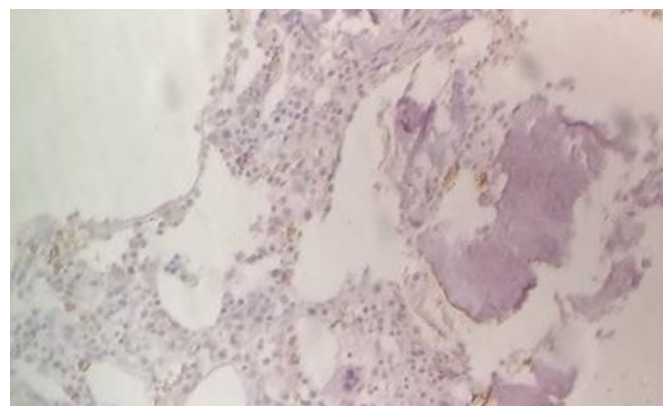


Figure 7: cells shows negativity for DTD maker

Discussion

Natural killer cell leukemia is a highly aggressive and extremely rare leukemia of NK cells with less than 200 cases reported worldwide [1]. It is more prevalent in Asia and South America accounting less than 1% of all the non-Hodgkin lymphomas with equal incidence for male and females. [2] Median survival rate for these patients is less than 2 months and having strong correlation with Epstein Barr Virus (EBV) infection. It was first reported as a type of large granular lymphocytic leukemia 28 years ago [1].

According to WHO (2017), NK cell neoplasms include: Chronic lympho proliferative disorder of NK cells (usually in adults) and the malignant subtypes including extra nodal NK/T-cell lymphoma of the nasal type (ENKL) and aggressive natural killer leukemia (ANKL, usually in middle age, with constitutional symptoms, hepatosplenomegaly and raised LDH levels) [3,4]. Immunophenotypically, the latter exhibit stronger CD56-expression and usually more CD7 negative and CD16 negative, compared to the former subtype which is CD56 dim/negative CD16 positive. CD56 is a neural cell adhesion molecule, it is a sensitive marker for NK cells, as it is expressed very early on committed NK precursors and on more than 95% of mature NK cells; its strong expression is related to the invasion and poor prognosis of neoplasms. [4] The common symptoms and signs include fever, B symptoms, hepatosplenomegaly, disseminated intravascular coagulopathy (DIC), and hemophagocytosis. NK-cell malignancies generally show poor response to chemotherapy through high expression of multidrug resistance associated p-glycoproteins. There is no standard treatment currently available for advanced-stage patients. [5] In our case report patient presented with a short history of fever, generalized body weakness and constipation for one week with hepatosplenomegaly with increased LDH levels. Immunohistochemistry was performed on trephine, which showed a strong CD56, indicative of aggressive natural killer cell leukemia. It was rare one, as his age falls into the chronic type but he presented with an acute one with a short history and aggressive nature of disease. Unfortunately the patient did not receive any treatment for disease and expired during his hospital stay.

Conclusion

As it was a rare case that presented as a suspicion of chronic lymphocytic leukemia, therefore, it should be kept in mind while dealing with patients who have the specific clinical findings because it can present with varied spectrum of clinical presentations and investigations. So, a final diagnosis for leukemia's should always be made by combining the results of the morphology, immune-phenotyping, and immunohistochemical analysis correlating with clinical presentation.

References

1. Nazarullah A, Don M, Linhares Y, Alkan S, Huang Q. Aggressive NK-cell leukemia: A rare entity with diagnostic and therapeutic challenge. *Human Pathology: Case Reports*. 2016; 4: 32-37.
2. Dressler S, Mordstein V. Aggressive natural killer cell leukemia associated with hemophagocytic lymphohistiocytosis. *Blood*. 2016; 128: 2370.
3. Jin X, Xu Y, Zhang J, Li G, Huang D, Yang Y, et al. Aggressive natural killer cell leukemia or extranodal NK/T cell lymphoma? A case with nasal involvement. *Diagnostic pathology*. 2017; 12: 46.