

Bladder thigh fistula-rare presentation of conservatively managed extra peritoneal bladder rupture

Pragatheeswarane Murugavaithianathan; Kalpesh parmar*; Sudheer kumar Devana; Ravimohan Mavuduru

*Kalpesh parmar, MS, MCh

Assistant Professor, Department of Urology, PGIMER, Chandigarh.

Abstract

Pelvic fractures are associated with a 7% to 25% incidence of lower urinary tract injuries. In particular, bladder rupture associated with a pelvic fracture has been reported to be 5% to 10%, where as the incidence of pelvic fractures exceeds 80% in patients with bladder ruptures. However a bladder thigh fistula is a rare presentation of extraperitoneal bladder rupture. We present a case of urinary bladder thigh fistula following conservative treatment of extraperitoneal bladder rupture.


Keywords

Urinary bladder; fistula; pelvic fracture

Introduction

Bladder trauma associated with pelvic fracture is a known entity [1]. The type of injury depends upon the volume of urine contained in the bladder at the time of trauma and associated ligamentous or pelvic osseous injury [1]. In few cases delayed urinary tract fistulation can occur with bladder rupture being managed conservatively [2]. As a rare manifestation, patient may present with groin abscesses secondary to bladder thigh fistula as our index case. After a thorough literature search, we could find only two cases of groin abscess and three cases of bladder thigh fistula following conservative management of extraperitoneal bladder rupture. A high index of suspicion is required for early diagnosis and to provide better outcome [3-5].

A 35 year old female sustained closed pelvic fracture by falling from a tree. She presented to us with a discharging left thigh wound of two months duration. She had pelvic fracture three months prior to presentation and was managed conservatively. The discharge from the thigh wound increased in volume, became watery, similar to the urinary catheter drainage which reduced considerably. There was a large raw area over anterior and medial aspect of the left thigh with healthy granulation tissue (Figure 1). USG abdomen showed bilateral kidneys were normal and urinary bladder was collapsed with Foleys catheter in situ. No evidence of collection was present. Analysis of discharge fluid revealed raised creatinine of 12 mg /dl suggestive of urine extravasation. X ray KUB showed left superior and inferior pubic rami fracture. CECT Abdomen with CT urography revealed extraperitoneal urinary bladder rupture with a rent 2 x 2 cm from the left anterolateral aspect of the bladder with contrast extravasation tracking along the left inguinal region into the left thigh wound. (Figure 2,3) After adequate preparation, patient had



exploratory laparotomy. Findings included a 2x2.5cm laceration on the left lateral wall of the urinary bladder with ragged edge, discharging urine. The edges of the bladder wound was excised and closed in two layers with vicryl suture (Figure 4). The leakage from the thigh wound stopped soon after the bladder repair and patient postoperative condition was uneventful. She has remained stable and voiding per urethra 3 months after discharge from the hospital.

Discussion

Urinary bladder injury may occur following blunt or penetrating trauma. Penetrating injuries represented 10- 20% and blunt trauma comprises 80-90% of cases of rupture of the bladder in the most recent studies [1]. Traumatic bladder injuries are classified either as contusion, extraperitoneal, intraperitoneal and combined extra- and intraperitoneal ruptures. Extraperitoneal ruptures are found alone in 62% of cases and in combination with intraperitoneal ruptures in another 12% [2]. Most of the cases are extraperitoneal bladder rupture and are managed with catheter drainage alone [6]. Vanderbilt University experience, published in 1995 reported significant (26%) complications in those managed conservatively, including vesicocutaneous fistula (3%), failure to heal (15%), and sepsis in one case leading to death [7]. Patients with unstable pelvic fracture usually had a poor outcome if not managed early. Surgical indications for extraperitoneal bladder ruptures include concomitant injury to the vagina or rectum, injury to the bladder neck, avulsion of the bladder neck, or cases with a foreign body in the lumen of the bladder such as a bone spicule from a pelvic fracture [8]. The common causes of vesicocutaneous fistula include extensive trauma with pelvic fractures, after irradiation for pelvic malignancies and postoperative causes like diverticulectomy [9]. Fistulography, cystography and cystoscopy can be helpful in diagnosing and localizing the site of fistula and MRI and CT are becoming increasingly useful for diagnosis, and are considered to be the primary test in some cases [10-12].

In our index case, patient had pelvic fracture 3 months back followed by which she developed groin abscess. Incision and drainage was done and there was bladder thigh fistula from the main wound. CT revealed extraperitoneal bladder rupture with vesico cutaneous fistula tracking to groin wound. Extravasated urine tracks from the perivesical space to groin by continuation under scarpas fascia. Further spread down the thigh is limited by attachment of scarpas fascia with fascia lata. Hence collected urine in groin can form abscess and if drained without addressing the underlying cause can lead to fistula formation. In our case we have emphasized about the anatomical basis and need for early surgical intervention in selected cases of extra peritoneal bladder rupture. This case is reported because of its rarity and unusual presentation. This is a rare presentation of traumatic extraperitoneal bladder rupture and a rarer indication for repair.

Figures

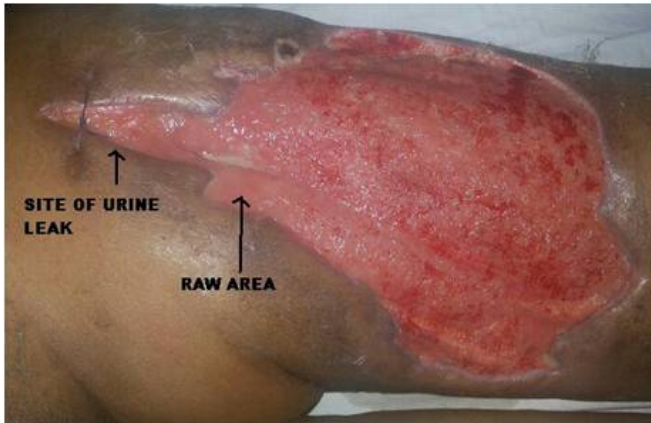


Figure 1: Left thigh wound with healthy granulation tissue and site of urine leak

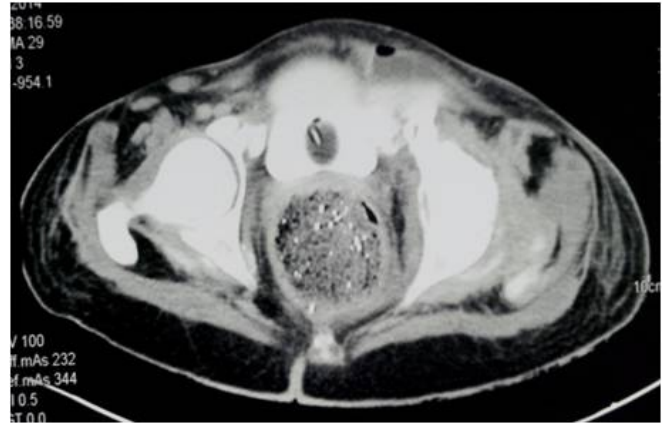

Figure 2: Left thigh wound with healthy granulation tissue and site of urine leak

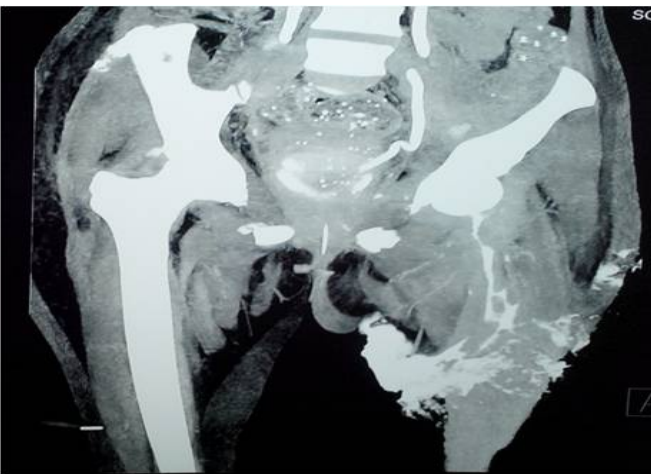


Figure 3: Left thigh wound with healthy granulation tissue and site of urine leak

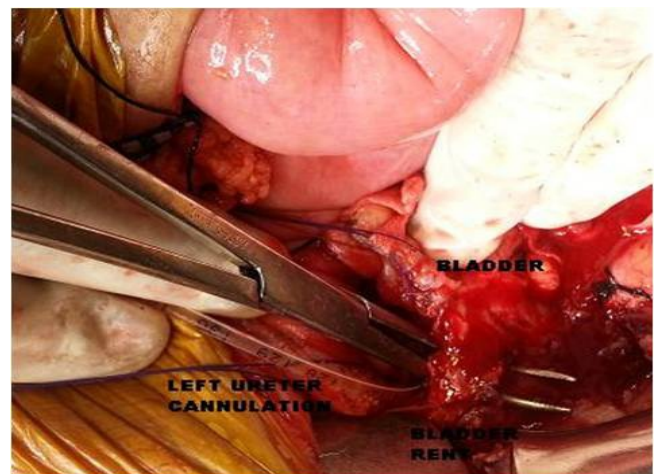


Figure 4: Intra operative image showing the bladder rent and left ureteric cannulation

References

1. Wessel N, Medby PC, Hoffmann L. Bladder rupture: diagnosis, etiology and treatment. *Tidsskr Nor Lægeforen*. 1995; 115: 2784-5.
2. Carroll PR, Mc Aninch JW. Major bladder trauma: Mechanisms of injury and a unified method of diagnosis and repair. *J Urol*. 1984; 132: 254- 257.
3. Banihani MN, Al-Azab RS, Waqfi NR, Kharashgah MN, Al Manasra AR. Vesicocutaneous fistula presenting as a thigh abscess. *Singapore Med J*. 2009; 50: e336-7.
4. Kim SB, Jung WK, Song DI, Lee SH. Vesicocutaneous fistula presenting groin abscess and chronic osteomyelitis in pubic bone. *Clin Orthop Surg*. 2009; 1: 176-9.
5. Kosaka T, Asano T, Azuma R, Yoshii H, Yamanaka Y, Hayakawa M. A case of vesicocutaneous fistula to the thigh. *Urology*. 2009; 73: 929.
6. Cass AS, Luxenberg M. Management of extraperitoneal ruptures of bladder caused by external trauma. *Urology*. 1989; 33: 179-183.
7. Kotkin L, Koch MO. Morbidity associated with nonoperative management of extraperitoneal bladder injuries. *J Trauma*. 1995; 38: 895-898.