

# Primary cavernous hemangioma of parotid

Betina Chandolia; Manas Bajpai\*; Manika Arora

\*Manas Bajpai

Associate Professor, Dept of Oral and maxillofacial Pathology, NIMS Dental College, Jaipur (India)

## Abstract

Haemangioma is a benign neoplasm of vascular phenotype. 65% of haemangiomas have been noted to occur in the head and neck and mainly salivary glands are affected. The parotid gland is the most common site with hemangiomas comprising of 0.4-0.6% of parotid gland tumors. Salivary gland haemangiomas in adults are of the cavernous type while infantile haemangiomas are of the capillary type. We present a case of cavernous haemangioma in left parotid region in of 39 year old male.

## Keywords

parotid tumor; cavernous haemangioma; lobular pattern

## Introduction

Haemangioma is defined as a benign neoplasm of vascular phenotype. 65% of haemangiomas have been noted to occur in the head and neck. Mainly salivary glands are affected with the parotid being the most common site. Haemangiomas comprises of 0.4-0.6% of parotid gland tumors, the majority of which occur in children and very rarely occur in adults. [1,2]. The female: male gender ratio of occurrence is 2:1 [3].

Histopathologically they are classified as capillary, cavernous and compound hemangiomas. Capillary hemangiomas are the commonest histological type of hemangioma characterized by collection of numerous small capillaries that are normal in size and lined by endothelial cells. Cavernous hemangiomas are made up of larger dilated blood vessels filled with blood. Compound hemangiomas is a term which is used to designate the hemangioma that shows combined features of capillary and cavernous types [4,5]. Here, we report a case of cavernous haemangioma in the left parotid region of 39 year old male.

## Case Report

A 39 year old male presented with a complaint of facial swelling at the left inferior parotid region since one year. The swelling was painless and did not increase or decrease with movement. On clinical examination, a 4 x 2 cm the swelling was soft, painless, non-fluctuant, non-pulsatile mass without trophic changes was found (Figure 1). Fine Needle Aspiration (FNA) and Ultrasound (US) imaging were done. FNA showed lymphocytes along with red blood cells (RBC) (Figure 2). US imaging showed a separated cystic mass (Figure 3).



On the basis of clinical and radiological examination, a provisional diagnosis of benign parotid tumor was given. Left superficial parotidectomy was carried out. At the time of surgery, the macroscopic appearance was hemorrhagic and well-defined which led to the suggestive diagnosis of a vascular lesion.

Microscopic appearance showed tumor with vascular proliferation that and showed a lobular pattern. Large vascular sinusoidal spaces containing red blood cells were seen. The flattened endothelium lining the vessels was without atypia and supported by a dense thin-walled collagen layer (Figure 4a&4b). All of these features suggested a diagnosis of cavernous haemangioma of the parotid gland.

## Discussion

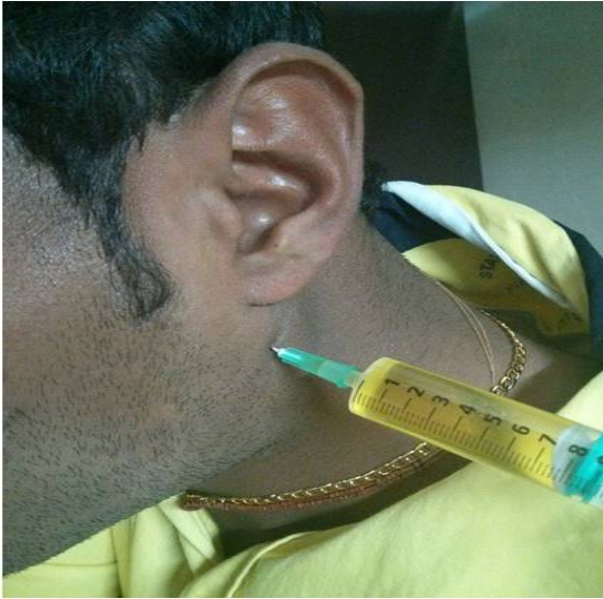In adults, parotid haemangiomas are rare [6]. Salivary gland haemangiomas are of the cavernous type in adults while infantile haemangiomas are mostly capillary type [4-6]. Haemangiomas are believed to be benign and congenital neoplasms, which are detected at the time of sudden growth which causes pain or cosmetic deformity. Otherwise they may be undetected for long periods of time. Development of haemangiomas may be from the gland proper, or by invasion of subcutaneous blood vessels into the gland structure. Clinically, Male to Female gender occurrence ratio is 1:2. The majority of the cases occur before the fourth decade of life. The age of the patient in our case was 39 years. The tumor mass usually presents as slow growing, soft or firm, movable, painless mass. In this case, the swelling was soft, painless, non-pulsatile, and non-movable, and without any trophic changes. Depending on the size of the haemangioma or in the case of acute hemorrhage or thrombosis, severe pain and swelling may occur. The size of cavernous haemangiomas can vary with pregnancy and menarche which may be due to response of endothelial cells to circulating hormones [7]. Haemangiomas are heterogeneous hypoechoic lesions on ultrasound [8]. In our case US showed a cystic mass. Surgical excision is the preferred choice for small lesions. Superficial or Total parotidectomy is required for large cavernous haemangiomas [1]. In our case, the macroscopic appearance was hemorrhagic and well-defined. Microscopically, the tumor showed vascular proliferation with lobular pattern. Large vascular sinusoidal spaces containing red blood cells were seen. Flattened endothelium lined the vessels. No atypia was seen. Dense collagen layer was seen with a thin wall in between. All the above confirmed the diagnosis of cavernous haemangioma.

## Conclusion

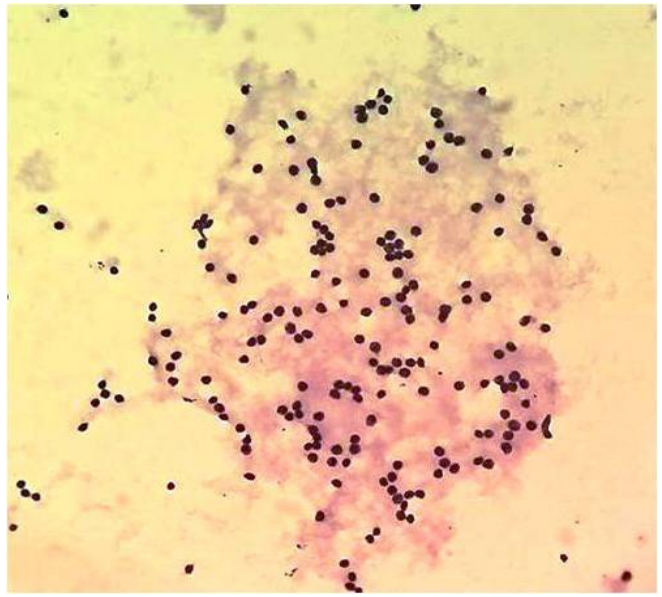
Haemangioma of the parotid mass is a rare entity in adults. It is usually undetected for a long periods of time unless it increases in size or there is a cosmetic deformity, discomfort, or pain. Surgical excision in the case of small lesions and superficial or complete parotidectomy is preferred in the case of large lesions.



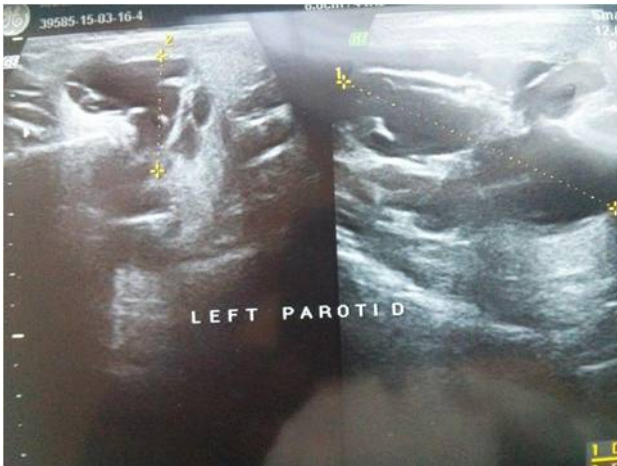## Figures



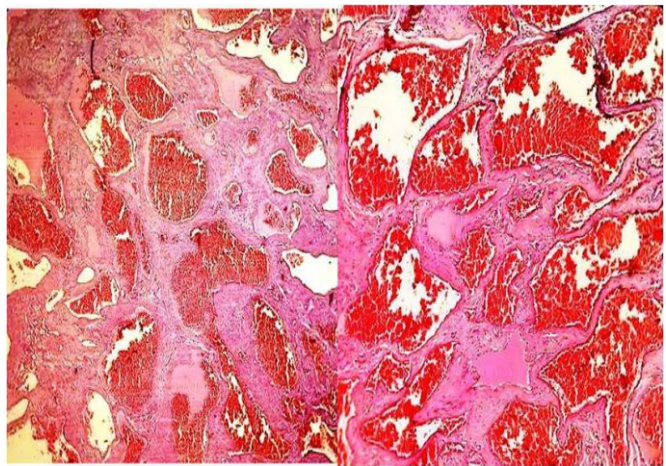
**Figure 1:** Clinical picture of the swelling on left inferior auricular region



**Figure 2:** FNAC picture showing lymphocytes along with Red blood cells



**Figure 3:** USG imaging showing cystic mass with parenchyma



**Figure 4:** Low power view shows vascular proliferation (Hematoxylin and Eosin staining X 10)  
**4b.** High power view shows showing large vascular sinusoidal spaces with red blood cells (Hematoxylin and Eosin staining X 40)

## References

1. Choi HJ, Lee JC, Kim JH, Lee YM, Lee HJ. Cavernous Hemangioma with large phlebolith of the Parotid Gland. *J Craniofac Surg* 2013; 24: 621-2.
2. Childers EL, Furlong MA, Fanburg-Smith JC. Hemangioma of the salivary gland: a study of ten cases of a rarely biopsied/excised lesion. *Ann Diagn Pathol.* 2002; 6: 339-44.
3. Bajpai M. Intra –osseous vascular tumor of mandible. *J Coll Physicians Surg Pak.* 2016; 26: 638.
4. Sanchez HL, Cagigal BP, Rubiales BM, Hernandez AV. Cavernous hemangioma of the parotid gland in adults. *J Clin Exp Dent.* 2014; 6: e592-4.
5. Bajpai M, Kumar M, Kumar M, Agarwal D. Pigmented Lesion of Buccal Mucosa. *Case Rep Med* 2014; 2014: 936142.