

# An adult case of incomplete shone's complex with parachute mitral valve and mitral ring

Chu Zhen Quek, MRCP\*; Hou Tee Lu, FRCP; Ji Yen Kam, MRCP; Benjamin Cheang Leng Leo, MRCP; Chuey Yan Lee, FRCP

\*Chu Zhen Quek

Department of Cardiology, Sultanah Aminah Hospital, Johor Baru, Malaysia

## Abstract

An adult young female presented with exertional dyspnoea. Her initial echocardiography showed rheumatic-liked mitral valve. There was diastolic flow across the mitral valve indicating mitral stenosis. At first, this echocardiography finding was mistakenly diagnosed as rheumatic mitral stenosis. However, the typical findings of commisural and subvalvular apparatus thickening seen in rheumatic valvulopathy were not seen at all. Further examination with 2D and colour Doppler in different echocardiographic views revealed 'parachute' mitral valve and other complex supralvalvular anomaly which lead to eventual diagnosis of shone complex which is an uncommon cause of congenital mitral stenosis in young adults.

## Keywords

parachute mitral valve; single papilla mitral valve; congenital mitral stenosis; supramitral membrane; mitral ring; shone complex

## Abbreviations

PMV: Parachute mitral valve

## Introduction

Shone complex is a rare disease. A Canadian registry (year 1982-2014) reported an incidence of this congenital heart disease to be 0.67% with the mean age of  $35 \pm 11$  years and among them, 50% are women [1]. Shone complex consists of a constellation of left-sided, usually obstructive, cardiac lesions, including mitral ring, PMV, subaortic stenosis, and aortic coarctation. The incomplete form is characterized by two or three of the above components. In the country of Malaysia, although rheumatic heart disease remains one of the most common causes of mitral stenosis [2], clinicians should be prudent to consider congenital mitral valve disease as the differential diagnosis.

## Case Report

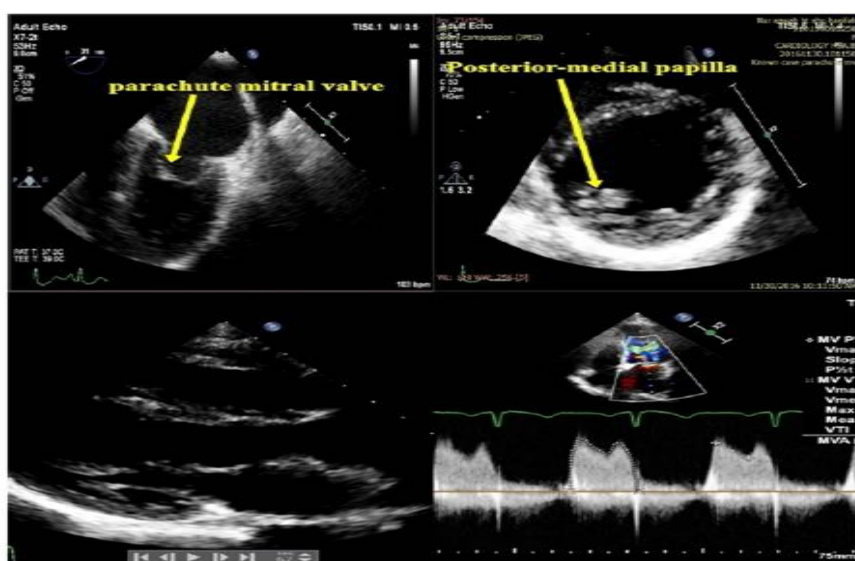
A 22-year-old Malay female presented with shortness of breath for three months. Her heart rate was regular and a grade II mid-diastolic murmur was heard over the mitral area. Transthoracic echocardiography of mitral valve showed partial excursion of the anterior mitral leaflet during diastole and normal posterior mitral leaflet excursion pattern. Both anterior and posterior mitral leaflets coapted well during systole. The mitral leaflets mimicked a "parachute" during diastole (Figure 1) on 2D

echocardiography. The Doppler examination of mitral inflow during diastole revealed moderate severity mitral stenosis with the mean pressure gradient of 10mmHg and the pressure half time of 167ms. At first, the echocardiography diagnosis of rheumatic mitral stenosis was made. However, apart from the abnormal diastolic excursion pattern, there was no other features of rheumatic valvulopathy such as thickening on the tips of the leaflets as well as subvalvular apparatus. The classical 'hockey-stick' sign seen in rheumatic mitral stenosis as the result of non-pliable tips of mitral leaflets, is absent. This rule out rheumatic aetiology. On careful examination of the subvalvular apparatus on 2D echocardiography, the chordae were seen converging on a single papillary muscle originating from posterior-medial segment best seen in the left ventricle on the parasternal short axis and apical four chamber views (Picture 1). On transoesophageal echocardiography, there was a thin layer of membrane/ring seen below the mitral valve. This membrane/ring was not visible on transthoracic echocardiography in the earlier examination. Colour Doppler revealed the origin of diastolic flow turbulence was at the level of the membrane/ ring rather than the mitral commissures (Picture 2). The aortic valve was tricuspid and no sub aortic membrane seen. There was no coarctation of aorta. The overall finding was consistent with incomplete Shone's anomaly [1] (PMV and supramitral ring). Patient responded well to low dose oral Furosemide. She had NYHA class 1 on the subsequent visit two months later. She had been referred to cardiothoracic team for consideration of surgical repair.

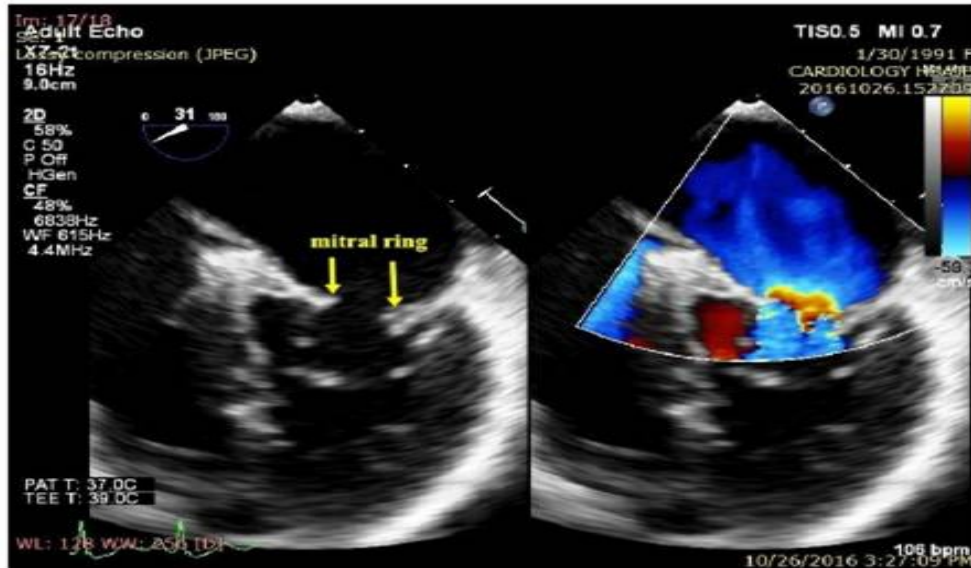
## Discussion

Shone complex is associated with relatively low mortality in adulthood but substantial morbidity is related to arrhythmias, heart failure, and interventions [1]. Other complications related to this disease are not well reported. Pubmed search showed two case reports with unique complications related to PMV. First case report is an adult with PMV complicated by thrombus attachment to the mitral leaflet [3]. Second case reported vegetation seating on the PMV in an adult patient [4]. Surgery remains the treatment of choice for symptomatic adult patient as demonstrated in most of the case reports.

## Figures



**Picture 1:** (Top left) Transoesophageal echocardiography 4 chamber view showing 'parachute' mitral valve. (top right) Short axis view of left ventricle papilla level showing only one single papilla arising posterior -medially. (bottom left) parasternal long axis view showing both the mitral leaflet converging on single papillary muscle. (bottom right) Doppler Study showing mean pressure gradient and pressure half time measurement.



**Picture 2** (left) supramitral membrane/mitral ring (arrows) seen below the mitral leaflet (right) colour doppler study showing turbulent flow originating from the subvalvular membrane

## Conclusion

This case report emphasized the need for a greater awareness regarding the rare incomplete Shone complex in adulthood, as it might occur far more frequently than might be expected following a random diagnosis. Increased awareness of this condition and associated complications may allow for successful diagnosis and tailored follow-up, respectively.

## References

1. Aslam S et. al. Shone Complex: An Under-recognized Congenital Heart Disease With Substantial Morbidity in Adulthood. *Can J Cardiol.* 33: 253-259.
2. LC Hung, Rajaram N. A. Review of Acute Rheumatic Fever and Rheumatic Heart Disease Research in Malaysia. *Med J Mal.* 2016; 71: 80-6.
3. Kawai Y, Yokoyama T, Hama G et al. Adult Case of Parachute-Like Asymmetrical Mitral Valve Complicated by Mitral Stenosis and Thrombus Formation. *Circ J.* 2017; 4: 1208-1209.
4. Showkathali R, Birdi I, Khokhar A. Infective endocarditis in a parachute-like asymmetrical mitral valve. *Eur J Echocardiogr.* 2009; 10: 476-478.