

Case series of bilateral pheochromocytoma

Santosh Kumar*; Pragatheeswarane Murugavaithianathan; Kalpesh parmar

*Santosh Kumar, MS, MCh, FRCS

Department of Urology, PGIMER, Chandigarh, India

Abstract

Pheochromocytomas are rare tumors, even rarer are bilateral pheochromocytomas. Bilateral pheochromocytoma could be a phenotype of multiple endocrine neoplasia (MEN) type 2, Von Hippel-Lindau (VHL) disease, familial pheochromocytoma-paraganglioma and neurofibromatosis (NF) type 1. We report five cases of bilateral pheochromocytomas (4 females, 1 male, age 19-40 years) operated in our centre. Of these cases, three cases were hereditary and two were sporadic. The hereditary cases had RET, VHL and SDHB gene mutations. Two patients underwent laparoscopic bilateral adrenalectomy and three patients underwent open bilateral adrenalectomy. One patient underwent cortical sparing adrenalectomy. Following surgery, all patients were normotensive. The patient who underwent cortical sparing adrenalectomy did not require steroid replacement. Management of bilateral pheochromocytomas requires a multidisciplinary team of urologist, endocrine surgeon, endocrinologist, and geneticist. Besides the health care management of the index patient, the risk of disease in relatives must also be adequately addressed.

Keywords

bilateral; pheochromocytoma; hereditary; sporadic; adrenalectomy

Abbreviations

MEN: Multiple Endocrine Neoplasia; VHL: Von Hippel Lindau; RET: Rearranged during Transfection; SDHB: Succinate dehydrogenase B; NF: Neurofibromatosis

Introduction

Pheochromocytomas are rare tumors, with an incidence of around 1 to 2 cases per 100,000 populations. Approximately 10% cases have bilateral tumors. Bilateral tumors are associated with certain genetic mutations. Bilateral pheochromocytoma could be a phenotype of multiple endocrine neoplasia (MEN) type 2, Von Hippel-Lindau (VHL) disease, familial pheochromocytoma-paraganglioma and neurofibromatosis (NF) type 1 [1]. The causal genes were discovered as *RET*, *VHL*, *SDHB*, *SDHD* and *NF1* respectively [2]. Each genetic syndromes share common characteristics such as early onset, multifocality and bilaterality, however, bilateral pheochromocytomas can also be sporadic. We hereby report five cases of bilateral pheochromocytomas.

Case Series

We present five patients of bilateral pheochromocytoma who underwent bilateral adrenalectomy

in Department of Urology, PGIMER, Chandigarh.

Case 1: A 29-year woman presented with history of intrapartum hypertension associated with headache and palpitations. Cross sectional CT imaging showed bilateral heterogeneous masses of size 55x43x37 mm in left and 37x25x25 mm in right suprarenal location (Figure 1). Endocrine workup showed elevated plasma free metanephrines of 137 pg/ml (Normal < 90 pg/ml) and normal free normetanephrines of 21.80 pg/ml (normal < 180 pg/ml). DOTATATE scan showed intense uptake in bilateral adrenals. Patient underwent bilateral laparoendoscopic surgery via a single umbilical incision while using conventional ports only. To avoid lifelong corticosteroid replacement bilateral cortical sparing adrenalectomy was performed. The blood loss was minimal and there were no perioperative complications. Patient was normotensive postoperatively without any anti-hypertensive medication. The pathological examination revealed bilateral benign adrenal pheochromocytoma (Figure 2). No steroid replacement was necessary in the post operative period.

Case 2: A 27 yr male, presented with episodes of anxiety for three years lasting for 15-20 minutes associated with palpitation and tremor of hands. He also complained of constipation since childhood associated with continuous dribbling of urine since 18 yrs of age, and recurrent urinary tract infections. He was diagnosed as having detrusor-sphincter dyssynergia with obstructive uropathy and underwent continent cutaneous urinary diversion in 2011. No other family member had similar complaints. On examination he had fleshy bumpy lips, multiple neuromas on tongue and buccal mucosa, right upper eye lid and enlarged cervical lymph nodes (Figure 3). There was no thyroid enlargement. Endocrine work up revealed elevated plasma metanephrine (1267pg/ml), normetanephrine (1141pg/ml) and calcitonin (5518pg/ml) levels. CECT abdomen showed bilateral suprarenal masses (Figure 3). Ascending and transverse colon were grossly dilated up to splenic flexure. Ultrasonography of neck showed 1.5x1.4cm hypoechoic lesion in upper pole of left lobe of thyroid along with multiple bilateral level II and level III nodes. Biopsy of cervical lymph node revealed metastatic neuroendocrine tumour. On DOTATATE scan, there was faint tracer uptake in bilateral level II,III cervical nodes, moderate tracer uptake in hypodense lesions in both lobes of thyroid gland, intense tracer uptake in right adrenal mass of size 4.6x4.1cm with areas of central necrosis, intense uptake in left suprarenal lesion of size 2.5x2.2cm. Patient underwent bilateral laparoscopic adrenalectomy and histopathological examination revealed bilateral benign pheochromocytoma. Patient had an uneventful postoperative recovery and was discharged on steroid replacement therapy. He did not require any antihypertensive medication in postoperative period. Patient was advised total thyroidectomy with lymph node dissection, but he was not willing for the same.

Case 3: A 19 years old female presented with dull aching bilateral hypochondriac pain for duration of 1 month. She did not have any episodic symptoms. No other family member had similar complaints. Her blood pressure was 160/100 mm Hg. Metabolic workup revealed normal metanephrine (55.63 pg/ml) and elevated normetanephrine (1141 pg/ml) levels. CECT showed a right suprarenal mass of size 4.6x4.6x4.6 cm and a left suprarenal mass of size 5.6x5.2x6 cm. In addition pancreatic head was diffusely bulky, with 3 ill defined hypervasular lesions, largest 15x15mm, suggestive of neuroendocrine tumor. DOTATATE scan revealed increased uptake in both adrenal masses and increased uptake in pancreatic head. MRI Brain, ultrasonography of neck and echocardiography were normal. No abnormality was detected in ophthalmic examination. Patient underwent bilateral adrenalectomy +

pancreaticoduodenectomy (Figure 4). Postoperative recovery of the patient was uneventful. She was discharged on steroid replacement therapy. Histopathological examination revealed bilateral benign pheochromocytoma and pancreatic neuroendocrine tumors.

Case 4: A 36years old female presented with dyspnea on exertion for 2 months. She had a single hypertensive episode, where her blood pressure reached 230/130 mmHg. She also complained of episodic diaphoresis, palpitation, headache for 15 days. Her elder brother, brother of grandfather, two sons of grandfather's brother also had pheochromocytoma. She had raised calcium levels (12.2 mg%). 24 hour urine metanephrine was normal, 178.9 μg (52-341). She had raised VMA, 24.2 mg(1.6-4.2) and Normetanephrine 6469 μg (88-444) levels. Serum PTH was raised, 145.6 pg/ml (8.0-69.0 pg/ml). USG neck revealed 1.8 x 0.8 cm well defined hypoechoic lesion in relation to right lobe of thyroid. CECT showed 2.3x1.9 cm lobulated lesion in aortocaval location. Left adrenal was bulky with a 15x12 mm lesion and 8mm lesion in right adrenal gland. MIBG scan showed increased uptake in both adrenals. Patient underwent open bilateral adrenalectomy with resection of interaortocaval mass. Patients postoperatively recovery was uneventful. She did not require antihypertensives in postoperative period. She was discharged on steroid replacement.

Case 5: A 40 years old female presented with pain in epigastric region for 3 years and headache on getting up from sitting position for 1 year. No family history of similar illness. Her blood pressure was 160/90mm Hg. Metabolic workup revealed elevated metanephrine levels (404 pg/ml) and raised urinary VMA levels(49 mg/day). CECT revealed bilateral adrenal mass (Right-5.5x10.5x6 cm and left 2.6x2.6x3.2 cm). DOTANOC scan revealed intense uptake in both adrenal masses. Patient underwent bilateral open adrenalectomy. Postoperative recovery of the patient was uneventful. Patient was normotensive postoperatively. She was discharged on steroid replacement therapy. Histopathological examination revealed bilateral benign pheochromocytoma with intense immunoreactivity for chromogranin in cells of pheochromocytoma (Figure 5).

Figures

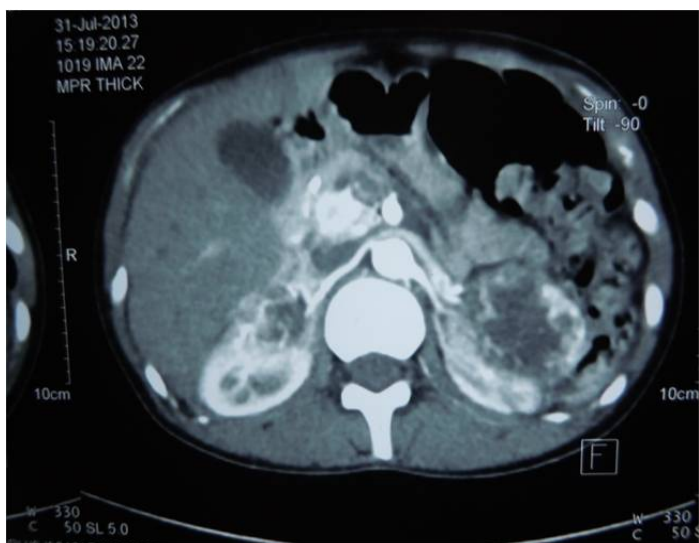


Figure 1: Cross sectional CT imaging showed bilateral heterogeneous masses of size 55x43x37 mm in left and 37x25x25 mm in right suprarenal location.

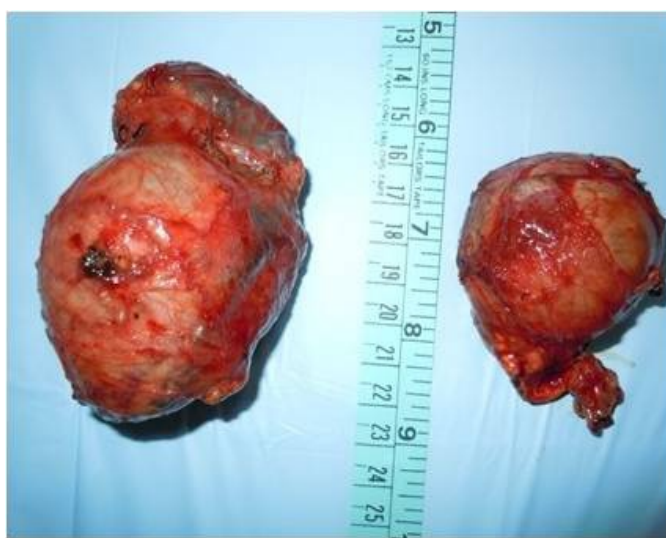

Figure 2: Resected tissue specimens of bilateral adrenals

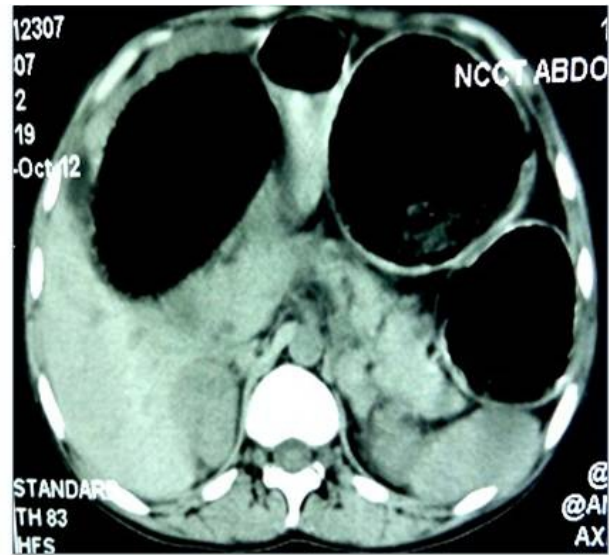
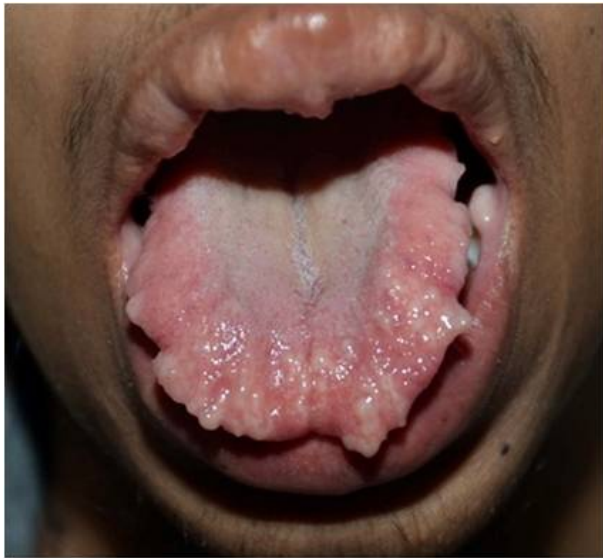

Figure 3: Multiple neuromas over tongue and CECT showing bilateral supra renal masses

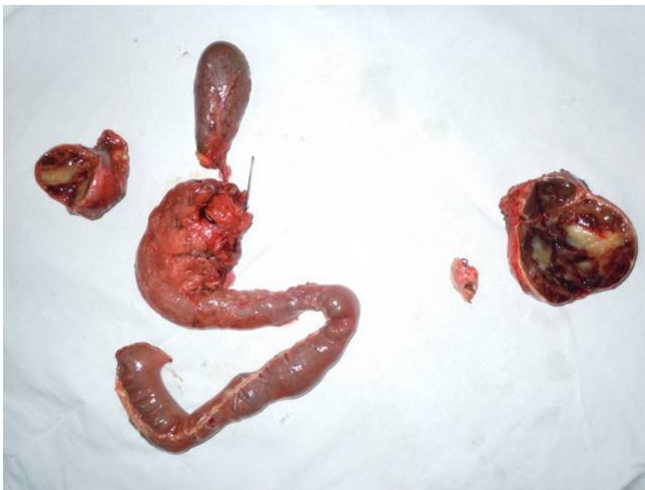

Figure 4: Final specimen of pancreaticoduodenectomy and bilateral adrenal excision.

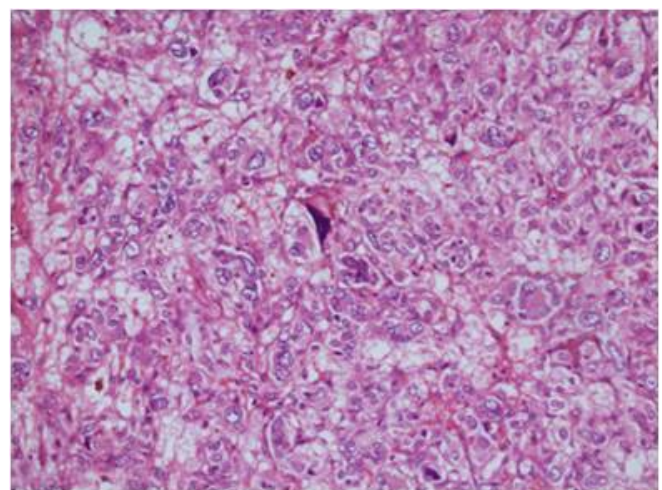


Figure 5: Histopathology showing intense immunoreactivity for chromogranin in cells of pheochromocytoma

Results

Out of five patients, two patients underwent laparoscopic bilateral adrenalectomy and three patients underwent open bilateral adrenalectomy. One patient underwent Laparo Endoscopic Single site Surgery (LESS). All patients had uneventful postoperative recovery and were normotensive without the need of any anti-hypertensive medication. Histopathological analysis revealed benign pheochromocytomas in all five cases. Genetic analysis revealed RET, VHL and SDHB mutation in 3 patients and rest 2 cases were sporadic in nature. The patient who underwent cortical sparing adrenalectomy did not require steroid replacement.

Discussion

Bilateral pheochromocytoma are encountered in MEN type 2, VHL disease, familial pheochromocytoma-paraganglioma and NF type 1. In our series, the first patient had mutation in SDHB gene, the second patient had MEN2B syndrome and third patient had VHL disease. Three genes encoding subunits of the mitochondrial complex II (SDH complex), SDHB, SDHC, and SDHD have recently been found to be the underlying genetic cause of most familial cases of paragangliomas and of 8% to 50% of

apparently sporadic paragangliomas [3,4]. The typical age at tumor development in patients with the familial paraganglioma syndromes is in the late 20s to early 30s. In SDHB mutation carriers, paragangliomas develop most often in the abdomen, frequently in the head and neck, and less commonly in the chest and adrenal gland. The chances of malignant pheochromocytoma increases in SDHB mutation, approaching 100% in some studies [5]. As for other neuroendocrine tumors, malignancy cannot reliably be predicted based on tumor histology alone and is generally identified only by the presence of metastatic disease. SDHB mutation is inherited in an autosomal-dominant manner [6]. Our case with SDHB mutation did not have a positive family history and also had benign pheochromocytomas.

MEN2B is the rarest subtype of MEN2 and is associated with medullary thyroid carcinoma, pheochromocytoma (in upto 50% of patients), and a characteristic physical appearance that results from mucosal neuromas in the tongue, lips, and eyelids . The characteristic facial features include enlarged lips, a "bumpy" tongue, and eversion of the eyelids [7]. Often patients have a thin and lanky (marfanoid) body habitus. Patients with MEN2B frequently have thickening of the corneal nerves or ganglioneuromatosis of the gastrointestinal tract, which can result in abdominal distention, megacolon, constipation, or diarrhea. Patients with MEN2B have an identifiable RET mutation and inheritance pattern is autosomal dominant [8,9]. Our patient had the typical phenotypic features of MEN 2B syndrome and genetic analysis also revealed RET mutation.

VHL syndrome accounts for around 50% of pheochromocytomas presenting before age 20 years and around 20% of cases result from a de novo mutations [10]. Risk of malignancy in phaeochromocytomas in VHL disease appears to be approximately 5%. Pheochromocytomas in VHL are characterized young age at onset, bilaterality, multifocality, raised normetanphrine, normalmetanephine levels [11]. The underlying genetic defect is within the VHL gene at 3p25. Inheritance pattern is autosomal dominant pattern [12]. Tumours are initiated by biallelic VHL inactivation leading to abnormal activation of hypoxic gene response pathways. In addition to pheochromocytoma, VHL is characterized by hemangioblastomas in the retina and central nervous system, renal cysts and clear cell renal cell carcinoma, pancreatic cysts and neuroendocrine tumors, endolymphatic sac tumors, and papillary cystadenomas of the epididymis ,broad ligament. Our patient had bilateral pheocromocytomas along with pancreatic neuroendocrine tumors and the genetic analysis revealed VHL gene mutation.

Regarding the surgical approach to the patient, laparoscopic minimally invasive approach has become the procedure of choice in cushing syndrome [13]. Laparoscopic transperitoneal adrenalectomy is now a safe and standardized procedure with a shorter learning curve and a similar low morbidity rate when compared to open surgical resection even for tumors larger than 6 cm [14]. Even in our case series we felt, laparoscopic approach had added advantage when compared to open adrenalectomy and should be the standard when feasible.

Conclusion

Hereditary causes of pheochromocytoma should be suspected in cases with bilateral functional adrenal masses. In such cases genetic tests should be carried out. Management of these cases requires a multidisciplinary team of urologist, endocrine surgeon, endocrinologist, and geneticist. Besides the

health care management of the index patient, the risk of disease in relatives must also be adequately addressed.

References

1. Bryant J, Farmer J, Kessler LJ, et al. Pheochromocytoma: the expanding genetic differential diagnosis. *J Natl Cancer Inst* 2003;95(16):1196–204.
2. Inabnet WB, Caragliano P, Pertsemlidis D. Pheochromocytoma: inherited associations, bilaterality, and cortex preservation. *Surgery* 2000;128(6):1007–11.
3. Gimenez-Roqueplo AP, Lehnert H, Mannelli M, et al. Pheochromocytoma, new genes and screening strategies. *Clin Endocrinol (Oxf)* 2006;65(6):699–705.
4. Brouwers FM, Eisenhofer G, Tao JJ, et al. High frequency of SDHB germline mutations in patients with malignant catecholamine-producing paragangliomas: implications for genetic testing. *J Clin Endocrinol Metab* 2006;91(11):4505–9.
5. Neumann HP, Pawlu C, Peczkowska M, et al. Distinct clinical features of paraganglioma syndromes associated with SDHB and SDHD gene mutations. *JAMA* 2004;292(8):943–51.
6. Baysal BE. Genomic imprinting and environment in hereditary paraganglioma. *Am J Med Genet C Semin Med Genet* 2004;129(1):85–90.
7. Schimke RN, Hartmann WH, Prout TE, et al. Syndrome of bilateral pheochromocytoma, medullary thyroid carcinoma and multiple neuromas. A possible regulatory defect in the differentiation of chromaffin tissue. *N Engl J Med* 1968;279(1):1–7.
8. Mulligan LM, Marsh DJ, Robinson BG, et al. Genotype-phenotype correlation in multiple endocrine neoplasia type 2: report of the International RET Mutation Consortium. *J Intern Med* 1995;238(4):343–6.
9. Gimm O, Marsh DJ, Andrew SD, et al. Germline dinucleotide mutation in codon 883 of the RET proto-oncogene in multiple endocrine neoplasia type 2B without codon 918 mutation. *J Clin Endocrinol Metab* 1997;82(11):3902–4.
10. Walther MM, Linehan WM. Von Hippel-Lindau disease and pheochromocytoma. *JAMA* 1996;275(11):839–40.
11. Eisenhofer G, Walther MM, Huynh TT, et al. Pheochromocytomas in von Hippel-Lindau syndrome and multiple endocrine neoplasia type 2 display distinct biochemical and clinical phenotypes. *J Clin Endocrinol Metab* 2001;86(5):1999–2008.
12. Stolle C, Glenn G, Zbar B, et al. Improved detection of germline mutations in the von Hippel-Lindau disease tumor suppressor gene. *Hum Mutat* 1998;12(6):417–23.
13. Conzo G, Pasquali D, Gambardella C, Della Pietra C, Esposito D et al. Long-term outcomes of laparoscopic adrenalectomy for Cushing disease. *Int J Surg*. 2014;12 Suppl 1:S107-11.
14. Conzo G, Tartaglia E, Gambardella C, Esposito D, Sciascia V, Mauriello C et al. Minimally invasive approach for adrenal lesions: Systematic review of laparoscopic versus retroperitoneoscopic adrenalectomy and assessment of risk factors for complications. *Int J Surg*. 2016 Apr;28 Suppl 1:S118-23.