

Giant cell tumour of a proximal phalanx treated with enbloc resection: A three-year follow-up

Buddhika Somawardana*; Sujeeva Weerasinghe; Bandujeewa Piyasena; Lalani De Silva

*Buddhika Somawardana

Senior registrar in Clinical Oncology, National Cancer Institute, Maharagama, Sri Lanka

Abstract

Giant cell tumours (GCT) of hand bones are rare (1.7%) [1]. Of the more than 2,400 skeletal GCTs reported in the literature, less than 50 were found to involve the phalanges of the hand. Involvement of metacarpal and phalangeal bones is associated with a higher risk of local recurrence [2]. We present a case report of GCT of the left middle finger proximal phalanx in a 26-year-old male treated with enbloc resection. At 3-year follow-up, there have been no recurrences or metastases.

Keywords

giant cell tumour; proximal phalanx

Introduction

Giant Cell Tumours (GCTs) of bone have been described as the most challenging benign bone tumor [3]. Although benign, GCTs show a tendency for significant bone destruction, local recurrence, and occasionally metastasis. The natural history of GCTs varies widely and can range from local bony destruction to local metastasis, metastasis to the lung, metastasis to lymph nodes, or malignant transformation [4,5].

Giant cell tumor is commonly seen in the epi-metaphyseal ends of long bones in young adults [6]. Rarely, it can occur in the bones of the hands and feet [7]. Tumors in these locations occur in younger patients and are associated with a higher risk of local recurrence than in tumors at the ends of long bones.

The majority of cases present as expansile lesions with associated pain [7]. Primary mode of therapy is surgical which ranges from curettage to excision to amputation [5].

Here we present a case of giant cell tumor of the left middle finger proximal phalanx noting the rarity and challenges in management at this anatomical location.

Case Report

A twenty-six-year-old gem businessman presented with a five-month history of progressive swelling on the dorsal aspect of his non dominant, left hand just proximal to the base of the middle finger. It started as a small swelling which rapidly progressed in size over 6 weeks. He complained of pain aggravated by movement of the finger. He had sought native ayurvedic treatment following which the swelling further worsened and ulcerated over a week.

Physical examination revealed a 6 × 6.5 × 4 cm ulcerated exophytic mass just proximal to the third and fourth web spaces with diffuse swelling and erythema of the proximal phalanx and base of the middle finger (**Figure 1**).

Contrast enhanced computed tomography (CT) scan of left hand showed a large expansile bony lesion with enhancing soft tissue component and a central cystic area involving the left middle finger proximal phalanx. There was evidence of bone destruction. The lesion extended into and involved the metacarpo-phalangeal joint with possible involvement of the metacarpal head. Distally the mass extended to the proximal interphalangeal joint but no distinctive joint involvement was seen. The flexor tendon of the middle finger also appeared to be involved.

Incisional biopsy revealed uniformly distributed osteoclast type multinucleated giant cells with proliferated spindle cell component. Significant numbers of mitoses were noted in stromal spindle cell component, but not in the multinucleated cells. There were no abnormal mitoses.

Enbloc resection was performed. The tumour was excised with the left middle finger and distal half of the metacarpal. Recovery was uneventful (**Figure 2**).

Histology of the amputated specimen confirmed the pathological diagnosis made by biopsy and a giant cell rich lesion (**Figure 3**) with proliferative activity of the mononuclear component and rich vascularity. There was no significant nuclear atypia.

The tumour infiltrated the adjacent skeletal muscle tissue. There was no evidence of tumour osteoid, frank cytological atypia or atypical mitoses typically seen in osteosarcoma.

Based on histological and radiological findings, the features were compatible with an aggressive, grade III GCT of bone. Resection margins were clear of tumour.

Chest radiograph and CT scan were normal. The patient has undergone regular follow-up for 39 months and has not shown any clinical and radiographic evidence of local recurrence or metastasis. His grip strength is subnormal, but with considerable functional recovery.

Discussion

GCT of the hand is rare. They recur more rapidly in the hand than they do in other locations. GCT of the phalanx is even rarer. Of the more than 2,400 skeletal GCTs reported in the literature, less than 50 were found to involve the phalanges of the hand [5,8-10].

The majority of these lesions have an ill-defined geographic pattern of bone destruction, but up to one third have a more aggressive moth-eaten pattern with cortical destruction and soft tissue infiltration. Aneurysmal cystic components and haemorrhage are noted in up to 24% of GCTs [11]. To avoid confusion in GCT diagnosis it is important to take into account not only histology but especially radiomorphology as well as anatomic location and patient age.

Giant cell tumors of the hand have been treated with curettage and cancellous bone grafting, wide resection, and structural bone grafting or ray amputation [9,10]. High local recurrence rates have been reported with these treatment modalities [10]. Enbloc resection was performed, given the extent of the lesion and the acceptable expected functional impairment in view of the patient's occupation. To avoid finger stiffness and tendon adhesion, we initiated active finger rehabilitation measures as early as the

second week. The patient was a gem businessman by occupation; the surgery did not significantly affect his occupation.

Most local recurrences of GCT cases of the hand are reported to occur within one year of primary surgery [12,13]. The overall prognosis is good. However, pulmonary metastases have been cited as the cause of death in 16-25% of reported cases [14].

Figures

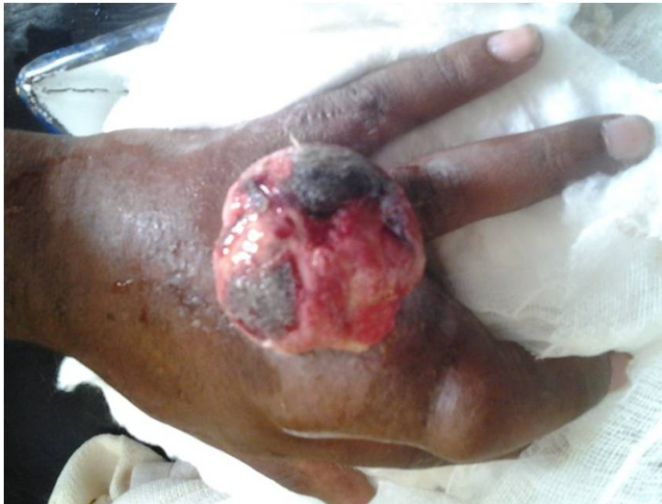

Figure 1: Large exophytic ulcerated mass proximal to the third and fourth web spaces with diffuse swelling and erythema of the proximal phalanx and base of the middle finger.

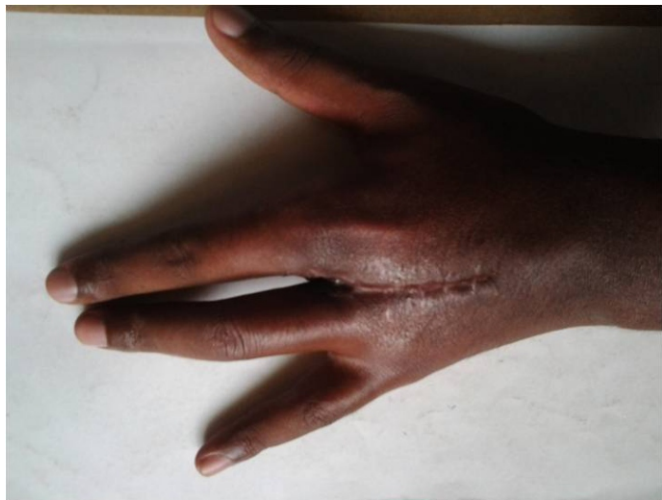

Figure 2: Post operative appearance of the left hand.

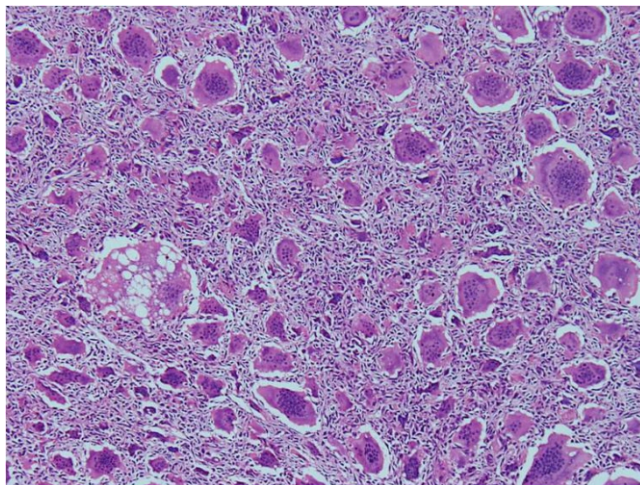


Figure 3: Giant cell rich lesion with increased proliferative activity of the mononuclear component and rich vascularity. No significant nuclear atypia seen.

References

1. Unni KK. Dahlin's bone tumors: general aspects and data on 11087 cases. 5th ed. Philadelphia: Lippincott-Raven, 1996: 263–83.
2. Soni R, Kapoor C, Shah M, Patel A, Golwala P. Giant cell tumour of the proximal phalanx of ring finger: case report and review of literature. Cureus. 2016 Oct; 8(10):e835.
3. McDonald SG. Surgery for Bone and Soft Tissue Sarcomas. NY:Lippincott Williams & Wilkins;1998:756.