

Oral Acanthosis Nigricans (AN) and Leser-Trelat sign (LT) in metastatic serous ovarian carcinoma: case report and review of literature

Zhi Mei Low*; Desmond Gan; Douglas Gin

*Zhi Mei Low

Monash Dermatology, Monash Health, VIC, Australia

Abstract

This is the first reported case of LT and malignant oral AN associated with ovarian carcinoma in a 69 year old lady. Oral lesions were initially missed by physicians and picked up only when referred to a dentist.

This article discusses the rarity of oral AN and the ongoing debate of LT as a paraneoplastic syndrome. Two literature reviews were carried out on malignant oral AN; and on reported LT cases between 2005 and 2016. It highlights the importance of clinical oral examination and emphasizes all clinicians to investigate for internal malignancies especially in cases with the coexistence of multiple cutaneous markers.

Keywords

Leser-Trelat; Acanthosis Nigricans; paraneoplasia

Introduction

Cutaneous changes can be the first sign of internal malignancy and there are many types of dermatologic manifestations of paraneoplastic syndromes. LT and malignant AN are examples of cutaneous paraneoplastic syndromes which can present as papulosquamous disorders [1]. Due to the lack of data and the fact that seborrheic keratoses are common findings in elderly patients, the relation between LT and internal malignancies remains debateable since it was first described in 1890. Malignant AN involving the oral cavity is rare and has been associated with aggressive malignancies such as gastric adenocarcinoma.

Here we discuss a patient with the coexistence of these cutaneous markers. We talk about the rarity of oral AN and the ongoing debate of LT as a paraneoplastic syndrome. We also highlight the importance of clinical oral examination and emphasizes all clinicians to investigate for internal malignancies especially in cases with the coexistence of multiple cutaneous markers. To the best of our knowledge, this is the first report of LT and malignant AN limited to the buccal mucosa in a patient with ovarian cancer.

Clinical Record

A 69-year-old Caucasian lady initially presented with a 12-month history of generalized eruptive seborrheic keratosis associated with pruritus and a new gradual onset of abdominal bloating. She also

complained of lower abdominal pain and constipation. She denied experiencing any B symptoms. Physical examination revealed xerotic skin and extensive seborrheic keratosis on the dorsum of both hands and lower limbs especially on the medial part of both thighs (Fig. 1 (a) and 2(a)). She also complained of a 2-year history of painful mouth associated with a cracked tongue. On oral examination, a thickened fissured tongue and buccal mucosa were noted (Fig. 3(a) and 4(a)). A shave biopsy showed compact hyperkeratosis with underlying epidermal papillomatosis and hypergranulosis. She was later referred to the Royal Dental Hospital for an oral biopsy. The oral pathology biopsy done showed squamous epithelial hyperplasia, with features which are not specific but would be consistent with oral acanthosis nigricans. Figure 5 shows the histopathological features of the buccal mucosa membrane.

She has a past history of fibromyalgia, osteoarthritis, anxiety/depression, asthma, GORD and Supraventricular Tachycardia (SVT). Her regular medications include Aspirin, Flecainide, Digoxin, Escitalopram, Meloxicam, Cyproheptadine, Pantoprazole, Tiotropium bromide and Budesonide/Formoterol inhalers. She does not have a smoking history and has a daily intake of 1 unit of alcohol daily.

In the setting of oral AN and LT with vague abdominal symptoms, a paraneoplastic syndrome was suspected and the patient was further investigated for internal malignancy. Prior to that, other common causes of AN were investigated and excluded. There was raised ESR of 112 and LDH of 258 and raised tumour markers [CEA of 62.3 ug/L, CA-125 of 1451 kU/L and CA 19-9 of 52 kU/L]. Gastroscopy, colonoscopy and bilateral mammogram were negative of malignancy. Computed tomography (CT) of the abdomen showed abnormal tissue above the fundus of the uterus and suspicious left axillary lymph nodes, suggestive a primary ovarian malignancy with peritoneal malignant disease with early spread into the right pleural space. A subsequent positron emission tomography (PET) scan showed similar findings of extensive, intensely avid peritoneal lesions compatible with peritoneal carcinomatosis and the distribution of mildly avid left axillary nodal disease. The axillary lymph nodes were later biopsied, suggesting metastatic high grade serous carcinoma of gynaecological origin.

A diagnosis of high grade serous ovarian carcinoma was made. She completed chemotherapy (Paclitaxel and Carboplatin) and later underwent laparotomy, total abdominal hysterectomy, bilateral salpingo-oophorectomy, omentectomy and debulking surgery in November 2015. To date, she remains in remission of ovarian cancer. A regression of oral AN was seen (Fig. 3(b) and 4 (b)). However, the cutaneous lesions seemed to remain unchanged (Fig. 1 (b) and 2(b)). She also reports that the pain in the mouth has resolved.

Discussion

Paraneoplasias are hormonal, neurologic or hematologic disturbances and other clinical and biochemical alterations, triggered by an altered immune response towards the neoplasm. It is not directly associated to the invasion by the primary tumour or by its metastases [2]. The pathogenesis of paraneoplastic syndromes remains poorly understood.

LT is a paraneoplastic syndrome characterised by sudden onset of multiple seborrheic keratosis. Pruritus is associated with 43% of the malignant cases [3,4]. The LT sign has been reported to appear from 5 months before cancer diagnosis to 9.8 months after [3]. This was consistent with the presentation

of our patient, which were pruritus and extensive seborrheic keratosis. However, our patient had a longer history of symptoms before the diagnosis. Since it was described in 1890, its validity remains a debate. Case control studies done by Fink et al in 2009, Grob et al in 1991 and Schwengle et al in 1988 showed no association between seborrheic keratosis and cancer respectively [5]. There have been 16 report cases of LT between 2005 and 2016, found via Ovid Medline (Table 1). 12 of them were isolated LT cases and the remaining cases were associated with other cutaneous paraneoplastic syndromes. There has only been 3 other case reports of LT found related to ovarian cancer [21-23]. In our patient, we did not notice a regression in seborrheic keratoses after completing treatment. This raises the question as to whether LT is a reliable paraneoplastic sign.

Malignant AN is characterized by the presence of hyperpigmented papillary lesions on the skin and oral papillomatous lesions [24]. Oral mucous membrane involvement has only been reported 40% of all AN cases [25]. Twenty two cases of malignant AN involving oral cavity were reported between 1968 and 2007 [24]. Between 2008 and 2015, there have been 6 reported cases of malignant AN involving the oral cavity, found via Ovid Medline and Scopus (Table 2). Gastric adenocarcinoma remains the most common associated malignancy. Malignant AN limited to the buccal mucosa is rare [24]. Only one case report of malignant AN involving ovarian cancer was reported in 2006 [21]. There have been only 3 case reports in 1963, 2004 and 2009 describing limited oral malignant AN [24,31,32]. We suspect that the lack of oral examination carried out by physicians may have contributed to the paucity of reports. This rare finding was seen in our patient, who had only oral mucous membrane involvement without skin manifestations of AN.

There have been many case reports on the coexistence of LT and AN. One in five patients with malignant LT also has acanthosis nigricans, which can present before, simultaneously or after a period of time [3,4,22]. Hyperkeratosis, acanthosis and papillomatosis are seen in both LT and AN [1,5]. The similar histological findings have led to the belief that the Leser-Trelat sign is an early stage of AN [3,4]. However this statement is arguable as the sign of LT has never been reported in association with benign AN [4]. Malignant AN and the sign of LT are commonly associated with gastric adenocarcinoma [16,24]. In our patient, we found similar histological findings but instead of gastric adenocarcinoma, she had carcinoma of a gynaecological origin.

Tumour-producing growth factors such as transforming growth factor- α (TGF- α), insulin-like growth factor 1 (IGF-1), fibroblast growth factor (FGF), melanocyte stimulating hormone- α (MSH- α) have been previously hypothesized to play an important role in the pathogenesis of AN and LT [1,26,28]. They are believed to stimulate keratinocyte growth via an endocrine route [26]. The genetic and environmental susceptibilities to malignant AN and the LT are poorly understood [4]. Yeh reports that genetic susceptibility may be implicated in both dermatoses as diffuse type gastric adenocarcinoma has a genetic susceptibility based on familial studies and its association with ABO blood group A. Yeh also believes that the increased association of either dermatosis with gastric adenocarcinoma may be due to the characteristics of the tumor mutagenesis producing the relevant inducer or because susceptibility to each of the 3 conditions is somehow linked, for example blood group A [4].

Conclusion

Cutaneous markers of internal malignancy have been well established for many years.

Unfortunately, there are still lack of data and research on the mechanism of cutaneous paraneoplastic syndromes. There are a considerable number of reported malignant AN cases but only limited number of oral AN cases. Most cases with oral involvement are usually first seen by dentists. The neoplasms associated with malignant AN are usually very aggressive in nature so all clinicians should be reminded of the importance of clinical oral examination. Clinical oral examination is especially important in rare cases of limited oral malignant AN like the patient in our case, where there are no other obvious cutaneous manifestations of AN. Missing the existence of a second cutaneous marker and due to the fact that seborrheic keratoses are common findings in elderly patients, further investigations for an internal malignancy may not have been carried out.

Until there are more studies on the mechanism of cutaneous paraneoplastic syndromes, we suggest all clinicians to investigate further for internal malignancy especially in cases with the coexistence of two cutaneous markers such as our case.

Figures

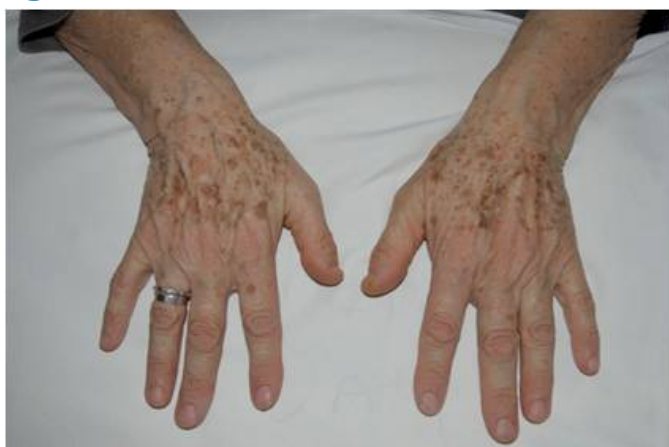

Figure 1(a): Seborrheic keratosis before chemotherapy.

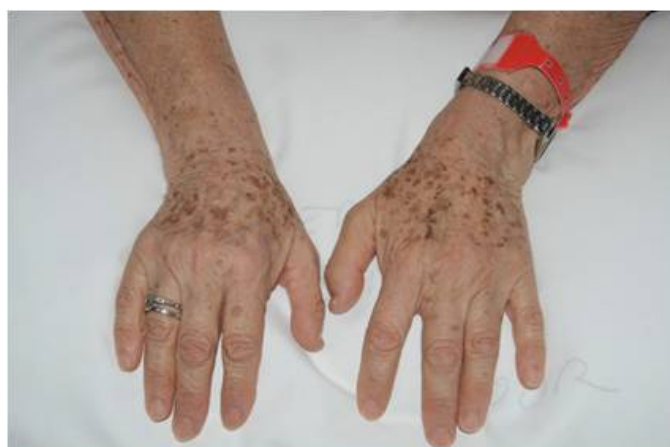

Figure 1(b): Seborrheic keratosis after completion of chemotherapy.

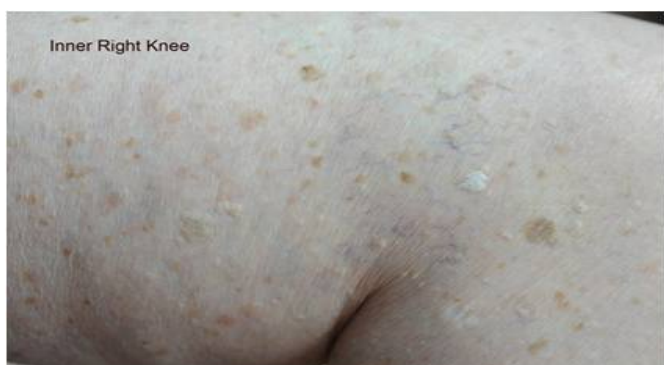

Figure 2(a): Right medial knee before chemotherapy.

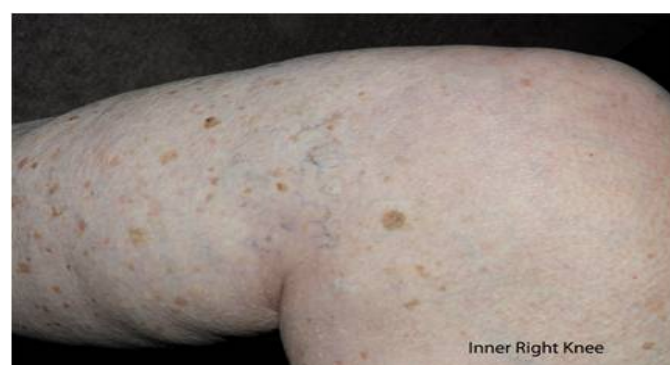

Figure 2(b): Right medial knee after completion of chemotherapy.

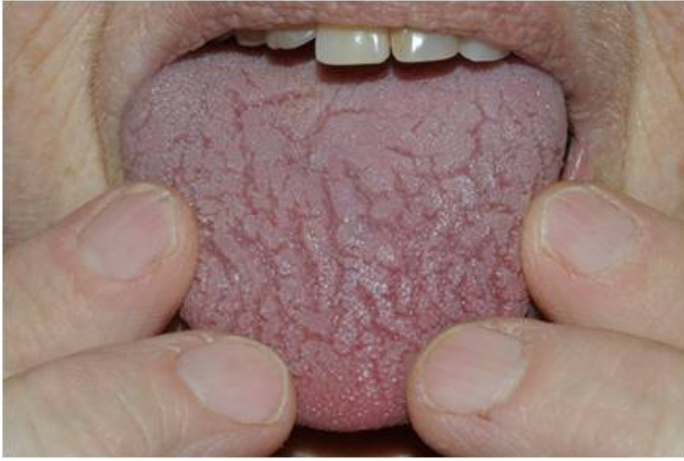

Figure 3(a): Tongue before chemotherapy.

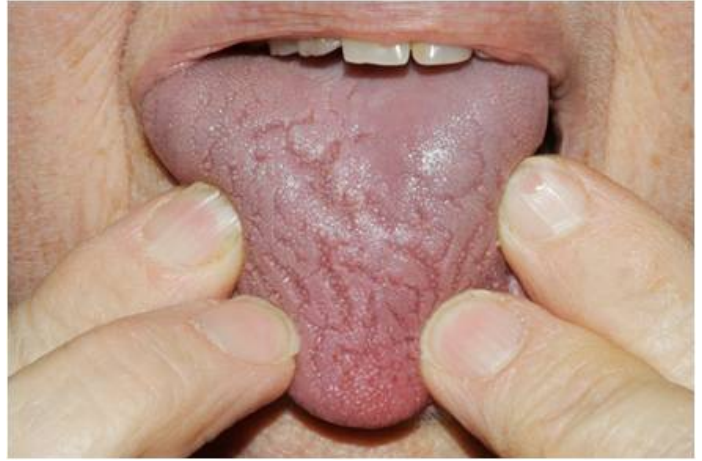

Figure 3(b): Tongue after completion of chemotherapy.

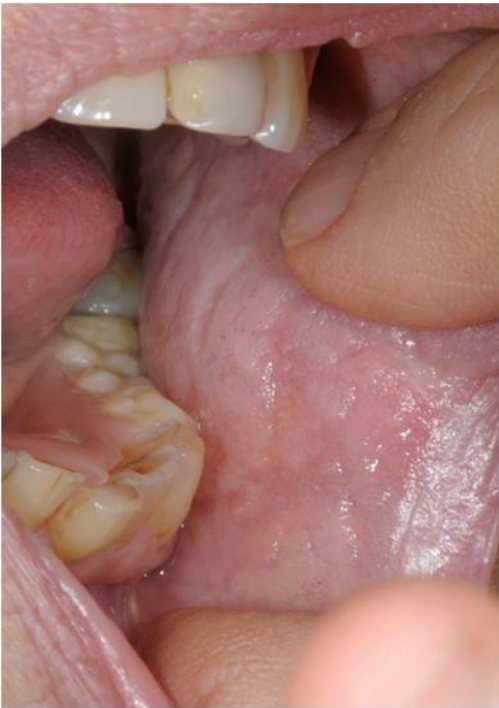

Figure 4(a): Buccal mucosa before chemotherapy.

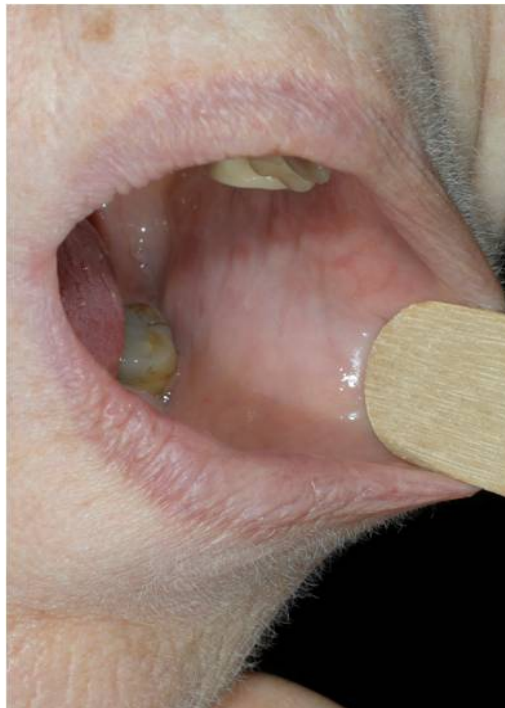

Figure 4(b): Buccal mucosa after completion of chemotherapy.




Figure 5: Histology slide of incisional biopsy of left buccal mucosa membrane. Squamous mucosa with hyperplasia, acanthosis, mild papillomatosis and minor parakeratosis of the squamous epithelium (HE; x100).

Tables

Table 1: Cases of LT between 2005 and 2016, via Ovid Medline.

Author Year of publication	Associated cutaneous paraneoplastic syndrome	Associated malignancy
Rowe et al. 2016[6]	-	Mycosis Fungoides
Li et al. 2015[7]	-	Primary hepatic carcinoma
Onajin et al. 2014[8]	Malignant acanthosis nigricans	Hepatocellular carcinoma
Abakka et al. 2013[9]	-	Uterine leiomyosarcoma
Al Ghazal et al. 2013[10]	-	Breast cancer
Van Marcke et al. 2013[11]	-	Multiple gastrointestinal neoplasia
Yavasoglu et al. 2011[12]	-	Acute myeloid leukemia
Constantinou et al. 2010[13]	-	Colorectal Adenocarcinoma
Ponti et al. 2010[14]	-	Gastric adenocarcinoma
Da Rosa et al. 2009[15]	Ichthyosis acquisita and Bazex Syndrome	Prostate adenocarcinoma
Siedek et al. 2009[16]	-	Malignant melanoma
Li et al. 2008[17]	-	Nasopharyngeal carcinoma
Nanda et al. 2008[18]	-	Gastric adenocarcinoma
Da Costa Franca et al. 2007[19]	Acanthosis nigricans and tripe palms	Benign hepatic neoplasia
Kocyigit et al. 2007[20]	-	Carcinoma of the gallbladder
Kebria et al. 2006[21]	Malignant acanthosis nigricans and tripe palms	Ovarian cancer

Table 2: Cases of malignant AN involving the oral cavity between 2008 and 2015, via Ovid Medline and Scopus.

Author Year of publication	Age	Gender	Oral signs and symptoms	Other signs and symptoms	Associated malignancy
This report	69	F	thickened fissured tongue and buccal mucosa	Eruptive seborrheic keratosis	Ovarian carcinoma
Yang et al 2013[26]	76	M	Papillomatous to verrucous plaques of lips and buccal oral mucosa	Florid cutaneous papillomatosis, Tripe palms	Gastric adenocarcinoma
Abu-Safieh et al 2011[27]	76	M	Papillomatous to verrucous plaques of lips and buccal oral mucosa	Florid cutaneous papillomatosis, Tripe palms	Gastric adenocarcinoma
Hagen et al 2011[28]	29	F	Diffuse papillomatous proliferations of lips	Velvety, hyperpigmented axillae with warts	Gastric adenocarcinoma
Hagen et al 2011[28]	62	F	Oral papillomatosis	Florid cutaneous papillomatosis, hyperpigmented plaques in the flexural areas, Sudden eruption of multiple itching, seborrheic verrucous lesions (Leser-Trelat)	Gastro-esophageal junction adenocarcinoma
Yamada et al 2010[29]	60	F	Papillomatous proliferations of lip mucosa, buccal mucosa, gingiva and tongue	Dark brown diffuse pigmentation of hand and nape of neck	Gastric adenocarcinoma
Krawczyk et al 2009[30]	75	Not specified	Warts around mouth	Generalized pruritus, hyperpigmentation in the axillae, groins and scrotum	Gastric adenocarcinoma
Migogna et al 2009[31]	74	F	Diffuse micropapillary lesions on the hard palate and inner upper lips, cerebriform of right cheek	Tripe palms	Gastric diffuse large B cell lymphoma

References

1. Kurzrock R, Cohen PR. Cutaneous Paraneoplastic Syndromes in Solid Tumours. *The American Journal of Medicine*. 1995Dec; 99 (6): 662-671.
2. Ramos-e-Silva M, Carvalho JC, Carneiro SC. Cutaneous paraneoplasia. *Clinics in Dermatology*. 2011 Sept; 29(5): 541-547.
3. Chung VQ, Moschella SL, Zembowicz A, Liu V. Clinical and pathological findings of paraneoplastic dermatoses. *JAm AcadDermatol*. 2006 May; 54 (5): 747.
4. Yeh JS, Munn SE, Plunkett TA, Harper PG, Hopster DJ, du Vivier AW. Coexistence of acanthosis nigricans and the sign of Leser-Trelat in a patient with gastric adenocarcinoma: a case report and literature review. *Journal American Academy Dermatology*. 2000 Feb; 42 (2 Pt 2): 357-62.

5. Turan E, Yesilova Y, Yurt N, Kocarsian. Leser-Trelat Sign: Does It Really Exist?. *Acta Dermatovenerol Croat*. 2013 Feb; 21 (2): 128-130.
6. Rowe B, Alina S, Gil Y. Leser-Trelat Sign in Tumor-Stage Mycosis Fungoides. *Dermatol Online J*. 2016 Apr; 22 (4).
7. Li JH, Guo H, Li B, Gao XH. Leser-Trelat sign with primary hepatic carcinoma. *Indian J Dermatol Venereol Leprol*. 2015 May-Jun; 81 (3): 320-321.
8. Onajin O, Comfere NI. Co-occurrence of malignant acanthosis nigricans and the Leser-Trelat sign in a patient with hepatocellular carcinoma. *International Journal of Dermatology*. 2015; 54 (5): 146-148.
9. Abakka S, Elhalouat H, Khoummame N, Achaaban M, ElAmrani S, Bargach S et al. Uterine leiomyosarcoma and Leser-Trelat sign. *Lancet*. 2013 Jan; 381 (9860): 88.
10. Al Ghazal P, Korber A, Klode J, Dissemond J. Leser-Trelat sign and breast cancer. *Lancet*. 2013 May; 381 (9878): 1653.
11. Van Marcke C, Lejeune S, D'Hondt L. A Leser-Trelat sign indicating multiple gastrointestinal neoplasia. *Acta Clinica Belgica*. 2013 Sept; 68 (5): 391-392.
12. Yavasoglu I, Kadikoylu G, Bolaman Z. The Leser-Trelat sign is associated with acute myeloid leukemia. *Ann Hematol*. 2011 Mar; 90 (3): 363.
13. Constantinou C, Dancea H, Meade P. The Sign of Leser-Trelat in Colorectal Adenocarcinoma. *The American Surgeon*. 2010 Mar; 76(3): 340-341.
14. Ponti G, Luppi G, Losi L, Giannetti A, Seidenari S. Leser-Trelat syndrome in patients affected by six multiple metachronous primitive cancers. *J Hematol Oncol*. 2010 Jan; 3:2.
15. Da Rosa AC, Pintos GM, Bortoluzzi JS, Duquia RP, de Almeida HL Jr. Three simultaneous paraneoplastic manifestations (ichthyosis acquisita, Bazex syndrome, and Leser-Trelat sign) with prostate adenocarcinoma. *J Am Acad Dermatol*. 2009 Sept; 61 (3): 538-540.
16. Siedek V, Schuh T, Wollenberg A. Leser-Trelat sign in metastasized malignant melanoma. *European Archives of Otorhinolaryngeal*. 2009 Feb; 266(2): 297-299.
17. Li M, Yang LJ, Zhu XH, Zhang YS, Sun H, Jiang PD et al. The Leser-Trelat sign associated with nasopharyngeal carcinoma: case report and review of cases reported in China. *Clin Exp Dermatol*. 2009 Jan; 34 (1): 52-54.
18. Nanda A, Mamon HJ, Fuchs CS. Sign of Leser-Trelat in Newly Diagnosed Advanced Gastric Adenocarcinoma. *J Clin Oncol*. 2008 Oct; 26 (30): 4992-4996.
19. Da Costa Franca AF, Siqueira NS, Carvalheira JB, Saad MJ, Souza EM. Acanthosis nigricans, tripe palms and the sign of Leser-Trelat in a patient with a benign hepatic neoplasia. *J Eur Acad Dermatol Venereol*. 2007 Jul; 21(6): 846-848.
20. Kocyigit P, Akay BN, Arica E, Anadolu RY, Erdem C. Post-renal transplantation Leser-Trelat sign associated with carcinoma of the gallbladder: A rare association. *Scand J Gastroenterol*. 2007 Jun; 42 (6): 779-781.
21. Kebria MM, Belinson J, Kim R, Mekhail TM. Malignant acanthosis nigricans, tripe palms and the sign of Leser-Trelat, a hint to the diagnosis of early stage ovarian cancer: a case report and review of the literature. *Gynaecologic Oncology*. 2006 Jan; 101 (2): 353-355.
22. Bolke E, Gerber PA, Peiper M, et al. Leser-Trelat sign presenting in a patient with ovarian cancer: a case report. *Journal of Medical Case Reports*. 2009 July; 3: 8583.
23. Holguin T, Padilla RS, Ampuero F. Ovarian Adenocarcinoma Presenting with the Sign of Leser-Trelat. *Gynaecologic Oncology*. 1986 Sept; 25 (1): 128-132.