

# Sjogren's syndrome induced pulmonary arterial hypertension and its treatment – A case report

Jean Rachel Samuel\*; Joji G Ponnachan; Jeena SK; Haritha SB; Fathima Shireen

\*Jean Rachel Samuel

Department of Pharmacy Practice, Grace College of Pharmacy, Kerala, India

## Abstract

Prevalence of primary-Sjogren's syndrome in the general population has been estimated to be around 1 to 3%. Nine out of ten Sjogren's patients are women. The most important complication is a 44-fold increase in the risk of developing non-Hodgkin lymphoma, compared with the general population. PAH due to Sjogren's syndrome to our knowledge is rare; only 32 cases have been reported in pSS patients to date. We here present you the case of a 30 year old women with Sjogren's syndrome and auto-immune hypothyroidism who has developed pulmonary arterial hypertension (PAH). So, we hereby draw your attention to the emergence of a rare complication of a rare disease such as Sjogren's syndrome and its management.

## Keywords

sjogren's syndrome; autoimmune disease; pulmonary abnormalities

## Introduction

Sjogren's syndrome (SS) is a systemic autoimmune disease that mainly affects the exocrine glands and usually presents as persistent dryness of the mouth and eyes due to functional impairment of the salivary and lacrimal glands [1,2]. Primary sjogren syndrome (pSS) characterized by sicca complex and extraglandular symptoms without any connective tissue disorder [3].

The pSS patients may develop pulmonary abnormalities such as interstitial lung diseases , airway disease, pleurisy, lymphoma, pseudolymphoma, amyloidosis, pulmonary vasculitis, granulomatous disease, and diaphragmatic myopathy. They may also develop the whole spectrum of lymphoproliferative disorders of the lung [4,5,6].

Standard PAH therapy includes the use of endothelin receptor antagonists, phosphodiesterase type 5 inhibitors, or prostanoids. While in case of treatment failures, first-line immunosuppressants can be added. Oxygen supplementation if hypoxemia occurs and diuretic therapy may be used to reduce the right ventricular preload [7,8]. Calcium-channel blockers used as short-acting vasodilator in idiopathic PAH was documented to be effective in less than 10% of patients [9].

Sjögren's syndrome has only rarely been reported from India [10,11]. Lung involvement in Indian patients with PSS has been described in isolated case reports [12]. Misra et al [13] reported a series of 15 PSS patients, diagnosed in the Rheumatology Clinic of a tertiary care hospital over more than 10 years

period. But, none of these patients was reported to have clinical lung disease possibly due to the absence of results of PFTs and lung imaging. Moreover there has been no perfect treatment strategy for PAH associated with pSS due to the small number of accumulated cases.

Hence below, we report the case of a 30 yr old woman with primary Sjogren's syndrome and autoimmune hypothyroidism who has developed pulmonary arterial hypertension.

## Case Presentation

A 30 year old female patient came with complaints of exertional dyspnoea. On lab investigations performed after 1 day of admission, she had features of polycythemia (Hb – 17.8g/dl). Facial features of B/L parotid gland enlargement was present. Patient worked up and was found to have severe PAH. Her ANA workup showed strongly positive (+++++) along with Schirmer's test (4mm/5min). RA factor was found to be negative and CRP was elevated.

**O/E:** At the time of admission, she has a BMI- 18. She looks thin and cachexic. Her BP was 90/70mmHG. Pallor is found to be positive. She has pinkish conjunctiva. No cyanosis or clubbing were present. On CVS examination there were features of Pulmonary Arterial Hypertension (PAH) including parasternal wave, Raised JVP, prominent C wave and pan systolic murmur of TR in epigastric region. RS – shows NVBS B/L. Per abdomen is normal.

The findings in Transthoracic Doppler Echocardiography were:

- 1- Grossly dilated right atrium, right ventricle compressing left ventricle
- 2- Good left ventricle systolic functions
- 3- Grade 1 diastolic dysfunction
- 4- No Regional Wall Motion Abnormality (RWMA)
- 5- Dilated Pulmonary artery (PA)
- 6- Moderate Pulmonary regurgitation (PR) and Tricuspid Regurgitation (TR)
- 7- Severe PAH
- 8- Mild Pericardial Effusion (PE) +ve

On Competitive Chemi Luminiscent Immuno Assay T3 and T4 levels were found to be 47ng/dl and 0.9µg/dl respectively. And TSH levels was found to be > 150µIU/ml.

Hence the physician diagnosed as severe PAH due to primary Sjogren syndrome with autoimmune hypothyroidism.

She was treated for PAH with Bosentan (62.5mg), an endothelin receptor antagonist and Thyroxine 25µg OD was given for hypothyroidism. She was again readmitted as her dyspnoea hadn't relieved. Nebulisation Salbutamol with Ipratropium Bromide and Budesonide is given Q 4H<sup>o</sup> and Oxygen 2L/min was administered. Tab. Nifedipine 20mg BD, a calcium channel blocker was added to the treatment regimen. Further Inj. Cyclophosphamide 250mg in 250ml NS stat (Pulse therapy) was given. She was discharged after 1 week and was advised to come for review after 1 month.

## Discussion

Cardiac involvement is not well established in primary Sjögren's syndrome. In more than one third of the patients the autoimmune process involves extraglandular sites with lymphoproliferative malignancy being its most frightening complication. Small series and case reports have already reported pericarditis, systolic and diastolic dysfunction of the left ventricle, valve disorders and autoimmune myocarditis [14-18].

This patient's echocardiography reveals presence of moderate valvular dysfunction, grade 1 diastolic dysfunction and mild pericardial effusion.

In a retrospective study [19] of all patients with pSS between January 1995 and January 2007 for PAH management. Among the 3 patients who were treated with calcium channel blockers (CCBs), there was 1 short-term failure, 1 probable stabilization with subsequent degradation and death and 1 probable short-term response. Hence the efficacy of CCBs are not confirmed. Bosentan improved dyspnea, 6-minute walk distance and right ventricular systolic pressure and is used for NYHA class III dyspnea. Standard PAH therapies, like endothelin receptor antagonists, type 5 phosphodiesterase inhibitors, or epoprostenol, can be efficient in pSS-associated PAH but that short-term or long-term treatment failure is possible and should be closely monitored.

Here our patient was treated with Bosentan (62.5mg) and Nifedipine (20mg) BD. And Further Inj. Cyclophosphamide 250mg in 250ml NS stat (Pulse therapy) was given.

IgG and complement have been identified in the pulmonary vessel walls from those patients [20,21], thus highlighting the use of immunosuppressants. Pulse steroid therapy has been suggested to be effective, ultimately by improving hemodynamic parameters and dyspnea functional class [22]. However, the use of high-dose cyclophosphamide raises some issues over the risk of severe adverse events and ovarian failure [23].

Launay *et al.*, [19] suggested the treatment algorithm of PAH associated with pSS. They proposed that initial immunosuppressive therapy (cyclophosphamide or azathioprine) should be taken in patients with NYHA class I/II dyspnea and immunosuppressive therapy; additionally, standard PAH therapy (endothelin receptor antagonists, phosphodiesterase-5 inhibitors or prostanoids) should be given to patients with NYHA class III/IV dyspnea.

The latest trends in the treatment of SS are as follows [24]:

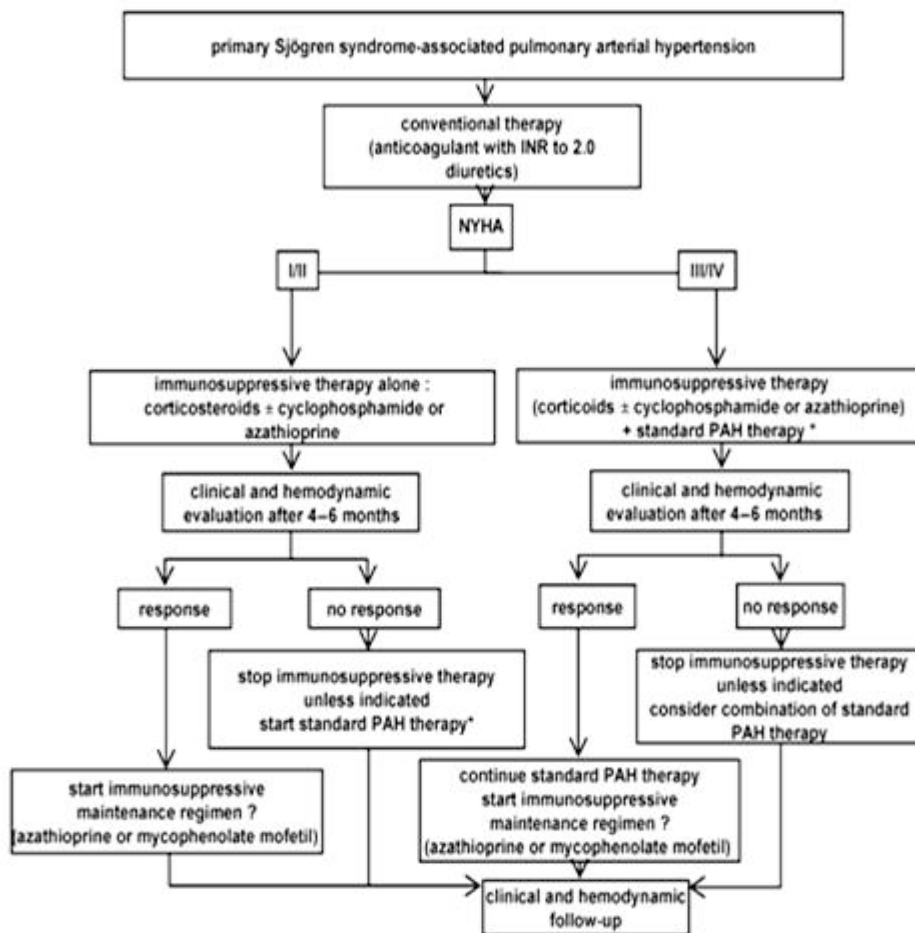
**Stem cells:** Current research into mesenchymal stem cells have shown remarkable promise in a wide array of treatments. This is done by taking and grows our own stem cells, and then returning them to better regulate a patient's existing immune system. This treatment is much safer than previous transplants. While research has been a bit quiet on the SS front, there have been promising studies around other autoimmune diseases, such as lupus and scleroderma, including animal studies published in summer 2015.

**Peptides:** These small proteins stimulate T-regulatory cells so that a patient's body corrects itself. The treatment has far fewer side effects than typical biologic drugs. Northwestern carried out a successful study on peptides in Lupus in 2013, and another lupus drug, Lupuzor entered phase 3 clinical trials in

December. According to preclinical findings, Lupuzor™ may also be effective in other chronic autoimmune pathologies, such as Sjögren's syndrome and Crohn's disease.

**Monoclonal antibody:** Rituximab has been successfully used in PSS patients with B-cell lymphomas with or without chemotherapy and may emerge as a first therapeutic choice as B-cells activation and antibodies formation are thought to play a role in the pathophysiology of pSS-associated PAH.

## Figure



**Figure 1:** Proposed treatment algorithm of pSS-associated PAH. This algorithm has not been validated by clinical studies. Efficacy of immunosuppressive therapy relies on weak retrospective data and should be ascertained by prospective randomized clinical trials. INR= international normalized ratio. \*Standard PAH therapy: endothelin receptor antagonists, phosphodiesterase type 5 inhibitors, or prostanoids; calcium channel blockers should be used only in patients who are true responders during the acute vasoreactivity test performed with the right-heart catheterization, as recommended by the guide lines.

## Conclusion

PAH due to pSS has been rarely reported from Indian literature. This is an isolated case report of a female patient who concurrently developed autoimmune hypothyroidism in our hospital. The patient was initially treated with Bosentan which showed only minor improvements. Further cyclophosphamide was added to it. Till now, there is no perfect treatment strategy for pSS which may be due to the little number of accumulated cases.

## References

1. M Ramos-Casals, A G Tzioufas, J Font. Primary Sjogren's syndrome: new clinical and therapeutic concepts. *Ann Rheum Dis* 2005;64:347–354.
2. Daniels TE, Fox PC. Salivary and oral components of Sjo'gren's syndrome. *Rheum Dis Cli North Am* 1992;18:571–89.
3. Pesaramelli Karteek, Anishetty Ranjith, Sravani Kethireddy. Sjogren Syndrome: A Review on Diagnostic Methods and Treatment Strategies. *World J Pharm Sci* 2016; 4(8): 203-206.
4. Pralay K. Sarkar<sup>1</sup>, Nick Patel<sup>1</sup>, Richard A. Furie, Arunabh Talwar. Pulmonary Manifestations of Primary Sjögren's Syndrome. *The Indian Journal of Chest Diseases & Allied Sciences* 2009;51:93-100.
5. Ji-An Hwang, Tae-Hyun Yang, Ji-Young Lee, Dong-Wan Koo, In Suk Choi, Sun-Young Cho *et al.*, Severe Pulmonary Hypertension in Primary Sjögren's Syndrome. *Korean Circ J* 2013;43:504-507.
6. Madelaine T Hedgpeth, Dennis W Boulware. Pulmonary hypertension in primary Sjogren's Syndrome. *Annals of the Rheumatic Diseases* 1988; 47:251-253.
7. Fuster V, Steele PM, Edwards WD, Gersh BJ, McGoon MD, Frye RL. Primary pulmonary hypertension: natural history and the importance of thrombosis. *Circulation* 1984;70:580-7.
8. Distler O, Pignone A. Pulmonary arterial hypertension and rheumatic diseases- from diagnosis to treatment. *Rheumatology* 2006;45(4):22-5.
9. Sanchez O, Humbert M, Sitbon O, Simonneau G. Treatment of pulmonary hypertension secondary to connective tissue diseases. *Thorax* 1999;54:273-7.
10. Chandersekar AN, Venugopal B, Thenmozhivilli PR, Partibhan M. Spectrum of clinical and immunological feature of systemic rheumatic disorders in a referral hospital in South India—Sjögren's syndrome. *J Indian Rheum Assoc* 1994;2:71-5.
11. Malaviya AN, Singh RR, Kapoor SK, Sharma A, Singh YN. Prevalence of rheumatic diseases in India: result of a population survey. *J Indian Rheum Assoc* 1994;2:13-7.
12. Marwaha V, Mohapatra S, Handa R. Sjogren's syndrome presenting with interstitial lung disease. *J Assoc Physicians India* 2005;53:153-4.
13. Misra R, Hissaria P, Tandon V, Aggarwal A, Krishnani N, Dabadghao S. Primary Sjogren's syndrome: rarity in india. *J Assoc Physicians India* 2003;51:859-62.
14. Gyongyosi N, Pokorny G, Jambrik Z, Kovacs L, Makula E, Csanady M: Cardiac manifestations in primary Sjögren's syndrome. *Ann Rheum Dis* 1996; 55: 450-4.
15. Rantapää-Dahlqvist S, Backman C, Sandgren H, Ostberg Y: Echocardiographic findings in patients with primary Sjögren's Syndrome. *Clin Rheumatol* 1993; 12: 214-8. 1993; 12: 214-8.
16. Levin Md, Zoet-Nugteren Sk, Markusse Hm: Myocarditis and primary Sjögren's syndrome. *Lancet* 1999; 354: 128. 1999; 354: 128.
17. Yoshioka K, Tegoshi H, Yoshida T, Uoshima N, Kasamatsu Y: Myocarditis and primary Sjögren's syndrome. *Lancet* 1999; 354: 1996.
18. Golan Td, Keren D, Elias N *et al.*: Severe reversible cardiomyopathy associated with systemic vasculitis in primary Sjögren's syndrome. *Lupus* 1997; 6: 505-8.