

# Termination of super refractory status epilepticus following cardiac arrest and septic shock: A case series

Rebecca Horrell, MS, ACNP; Megan Lange, MS, ACNP\*

\*Megan Lange, MS, ACNP

Department of Advanced Practice Nursing, University of Maryland Medical Center, USA

## Abstract

**Introduction:** Super-refractory status epilepticus, defined as seizures persisting despite anesthetics, is associated with high morbidity and mortality.

**Case Presentation:** Here we present two cases of super-refractory status epilepticus intractable to aggressive therapies, including but not limited to anesthetics, electroconvulsive therapy, and immunotherapy. In both cases, the patients developed sepsis and cardiac arrest following prolonged hospitalizations with subsequent termination of seizure activity. Following cardiac arrest, both patients exhibited improvement in electroencephalogram findings and neurologic exams.

**Discussion:** A review of the literature revealed multiple publications describing super-refractory status epilepticus as a result of sepsis or cardiac arrest, but there is limited literature discussing either complication as therapeutic for status epilepticus. We propose that the systemic effects associated with profound sepsis, or the brief electrographic silence occurring in the setting of cardiac arrest, could have played a role in halting seizures in these patients.

## Keywords

status epilepticus; super-refractory status epilepticus; cardiac arrest; pulseless electrical activity; sepsis; shock

## Abbreviations

SE: Status epilepticus; SRSE: Super-refractory status epilepticus; ECT: Electroconvulsive therapy; GTC: Generalized tonic clonic; CSF: Cerebrospinal fluid; HSV: Herpes simplex virus; MRI: Magnetic Resonance Imaging; PET: Positron emission tomography; PEA: Pulseless electrical activity; ROSC: Return of spontaneous circulation; CPR: Cardiopulmonary resuscitation; EEG: Electroencephalogram; SUDEP: Sudden unexplained death in epilepsy; SIRS: Systemic inflammatory response syndrome; CARS: Compensatory anti-inflammatory response syndrome

## Introduction

Status Epilepticus (SE) is defined as seizure activity lasting more than five minutes or as more than one seizure without return to neurologic baseline. Once first and second line anticonvulsant treatments have been administered without resolution of seizures, the SE is considered refractory [1]. Continuous infusions of anesthetics are generally used to suppress the persistent seizure activity. If seizure activity continues or recurs more than 24 hours after initiation of anesthetics, it is termed super-refractory status

epilepticus (SRSE) [2]. A recent retrospective study reported that 5-10% of patients in SE will progress to SRSE, with one year mortality rates estimated at 36% [3].

We present two cases of SRSE intractable to aggressive therapies, including but not limited to anesthetics, electroconvulsive therapy (ECT), and immunomodulatory therapy. In both cases, the patients developed septic shock and cardiac arrest following prolonged hospitalizations with subsequent termination of seizure activity.

## Case Series


### Case report (1)

A 26-year-old Caucasian male with no significant past medical history presented with four days of fevers followed by generalized pain and confusion that progressed to obtundation. On arrival to the hospital he was combative and agitated requiring haloperidol, and then developed generalized tonic clonic (GTC) seizures refractory to lorazepam, phenytoin, levetiracetam, and propofol. The patient had no prior history of seizures. Head imaging and cerebrospinal fluid (CSF) analysis were unremarkable and he was transferred to a tertiary care center for management of his SE.

Over the next five weeks, the patient continued to experience partial and GTC seizures, despite a treatment regimen of burst suppression with propofol (up to 75 mcg/kg/min) three times, high dose midazolam (up to 2.9 mg/kg/hr) one time, and high dose midazolam (up to 2.9 mg/kg/hr) with ketamine (up to 7.5 mg/kg/hr) three times. He also received two treatments of ECT, of which only the latter generated clinical and electrographic generalized seizures. Ketogenic diet was initiated, with ketosis achieved in his fifth week of hospitalization. He was unresponsive to a course of high dose steroids, and was consequently treated with a prolonged 10 treatment course of plasmapheresis. His antiepileptic regimen was advanced to levetiracetam 3000 mg twice daily, phenytoin 400 mg three times daily (free goal 2.5-3 mcg/mL), topiramate 200 mg twice daily, lacosamide 400 mg three times daily, phenobarbital 400 mg four times daily (goal level 60-80 mcg/mL), and clonazepam 4 mg three times daily. He also received magnesium (goal 3-4 mEq/L) and vitamin B6 supplementation.

On arrival to the tertiary care facility, the patient was started on acyclovir for possible herpes simplex virus (HSV), as well as vancomycin and ceftriaxone. Vancomycin and ceftriaxone were discontinued given benign CSF findings. He also received an incomplete course of Tamiflu for a viral prodrome, which was discontinued in the setting of a negative respiratory panel. He completed the 14-day course of acyclovir started prior to transfer for possible HSV, despite two negative HSV polymerase chain reaction (PCR) tests. He was also treated for possible human herpes virus 6 with a 14-day course of ganciclovir. Extensive diagnostic evaluation was benign, including unremarkable brain Magnetic Resonance Imaging (MRI), full body positron emission tomography (PET), muscle biopsy, and a negative scrotal ultrasound. Additionally, multiple CSF samples were benign and sent for extensive testing, including viral and paraneoplastic evaluation which were negative.

Despite exhaustive therapies and a negative work up, the patient continued to experience seizures each time burst suppression was discontinued. Seizures originated from both anterior temporal lobes with secondary generalization (Figure 1). Five weeks into his hospitalization, he had a gastrostomy tube placed, and the following day his anesthetics were weaned. Three days later, the patient developed septic



shock. He became acutely hypotensive requiring norepinephrine, epinephrine, and vasopressin infusions, and became profoundly acidotic (pH 7.0) with abdominal compartment syndrome. He was taken emergently to the operating room for exploratory laparotomy where the gastrostomy tube was noted to be dislodged and 4.5 liters of tube feeds were evacuated from the peritoneal cavity. Post-operatively, he had two pulseless electrical activity (PEA) cardiac arrests. Return of spontaneous circulation (ROSC) occurred following one round of cardiopulmonary resuscitation (CPR) and advanced cardiovascular life support during both events. Strict normothermia was maintained post-arrest, but therapeutic hypothermia was not initiated. Following his arrests, he had a single bilateral temporal electroclinical seizure captured on electroencephalogram (EEG), which otherwise only revealed moderate diffuse slowing with triphasic waves (Figure 2). The patient did not develop any further seizure activity during his hospitalization, and eventually regained a level of functional independence with only mild memory issues and critical illness polyneuropathy. Following discharge from the hospital the patient remained seizure free. He had a single readmission one year after discharge, for four seizures without return to neurologic baseline. This was in the setting of medication non-compliance and fevers, and he was discharged to home the following day. Unfortunately, approximately two years after his initial presentation, the patient was found pulseless in his bed. There was no clear etiology of his death, consistent with sudden unexplained death in epilepsy (SUDEP), a common complication of epilepsy in young people.

## **Case report (2)**

A 69-year-old African American male with a past medical history of hypertension and alcohol abuse initially presented to a hospital with seizure like activity in the setting of alcohol withdrawal. There was no reported history of seizures in the past. The patient was treated with levetiracetam and magnesium oxide before being discharged. On the evening following discharge, he was noted to be lethargic with left sided hemiparesis. Paramedics were called, and on arrival to the Emergency Department he was febrile with a leukocytosis and a urinalysis consistent with a urinary tract infection. He remained confused over the next four days, and developed abnormal left arm and facial movements prompting intubation and transfer to the intensive care unit. EEG revealed seizures arising from the right temporoparietal region. He was started on vancomycin, ampicillin, ceftriaxone, and acyclovir in addition to levetiracetam, valproic acid, and propofol for clonic movements. CSF analysis was unremarkable, however, clinical seizures persisted and phenytoin and lacosamide were added. The patient was then transferred to a tertiary care center.

Upon transfer, phenytoin was discontinued to allow for therapeutic levels of valproic acid, but levetiracetam, valproic acid, and lacosamide were continued. Despite this regimen, clinical and electrographic seizures persisted. Over the next five weeks, he received a treatment regimen of seizure suppression with propofol (up to 60 mcg/kg/min) two times, and high dose midazolam (up to 1.8 mg/kg/hr) and ketamine (up to 1.5 mg/kg/hr) two times. Additional interventions included a five day course of high dose steroids, and an incomplete course of plasmapheresis which was aborted after two treatments due to metabolic disturbances. He was also started on a ketogenic diet, with successful ketosis in week five of his hospitalization, and he was started on phenobarbital 100 mg twice daily (goal 40-60 mcg/mL). Phenobarbital was eventually discontinued so he could undergo three ECT treatments, all of

which failed to generate a seizure. His antiepileptic regimen was advanced to levetiracetam 2000 mg two times daily, lacosamide 200 mg twice daily, and valproic acid 1200 mg three times daily (total goal 50-70 mcg/mL).

The patient was initially treated with acyclovir, which was discontinued following two negative HSV PCR tests. Vancomycin, ampicillin, and ceftriaxone were also discontinued due to low suspicion of bacterial meningitis. He completed a course of high dose thiamine for possible Wernicke's Encephalopathy. Extensive CSF studies were sent for autoimmune, paraneoplastic, and infectious evaluation, which were all negative. MRI of the brain and full body PET scan were also negative.

Five weeks into the patient's hospital course, EEG revealed recurrent right posterior temporoparietal onset seizures without improvement in his neurologic examination, with occasional eye opening to pain and flaccid extremities (Figure 3). In the week following tracheostomy placement, bright red blood occluded his tracheostomy causing two PEA arrests with ROSC at 11 minutes and 6 minutes. Therapeutic hypothermia was initiated, and the patient was maintained at 35 degrees Celsius. After resuscitation the patient was noted to be in septic shock with peri-arrest cultures revealing pseudomonas in his bronchial washing, blood, and urine. Post-arrest EEG revealed posterior right lateralized pseudoperiodic discharges without further seizures (Figure 4). The patient's neurologic examination improved, and he was able to open his eyes and track, as well as follow commands with his right arm and leg. He remained seizure free to the following month, before being discharged to a rehabilitation facility closer to his family. As a result, he was lost to follow up and his long term neurologic outcome is unknown.

## Discussion

We presented two clinical cases in which SRSE resolved following cardiac arrest and septic shock. A review of the literature revealed multiple publications focusing on SRSE as a result of septic shock or cardiac arrest. Only one publication, however, was found that described cessation of SRSE following cardiac arrest [4]. In that case, the patient remained in a persistent vegetative state. No other reports were found in the literature describing this phenomenon. There is not a clear mechanism of action to explain how cardiac arrest or septic shock could lead to termination of SRSE.

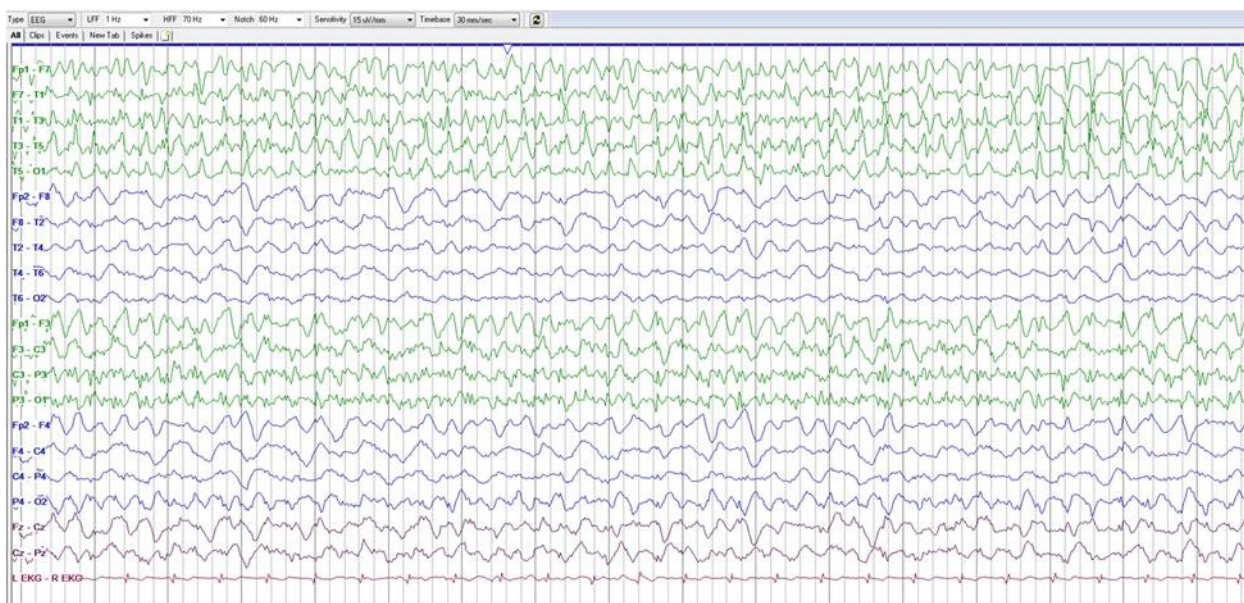
Cardiac arrest has long been cited as one of the most common causes of SE [5]. It would be counterintuitive, then, that cardiac arrest could actually be responsible for the cessation of seizures in both cases. Nonetheless, it is possible that the transient profound acidosis associated with cardiac arrest may have played a role in seizure termination. Several studies, as far back as 1929, have focused on acidosis and its role in eliminating seizure discharges in epileptic patients [6]. Additionally, there is some evidence to demonstrate that hypercarbia may also provide some utility in seizure suppression [7]. Further research is necessary, however, to better understand the association between hypercarbic acidosis and seizures. Cardiac arrest could also have contributed to seizure termination by generating brief electrographic silence on EEG as a result of hypotension and hypoperfusion. Theoretically, this silence would aid in preventing excitotoxicity and halt seizures, much like general anesthetics. Since both patients had failed multiple trials of burst suppression, this was likely not the mechanism by which seizures were halted.



An alternative possibility is that both patients' seizures were halted by the systemic effects of overwhelming sepsis. The role of inflammation in status epilepticus has been widely described, with immunomodulatory therapies being used to treat SRSE, including anesthetics and corticosteroids. The systemic inflammatory response syndrome (SIRS) is the early pro-inflammatory phase of sepsis. This phase leads to breakdown of the blood brain barrier and is responsible for many seizures seen in the intensive care unit [8,9] making a hypothesis that sepsis could contribute to the cessation of SRSE counterintuitive. Over the last several decades, however, research has focused on an alternate pathway aimed at deactivating the immune system and ensuring homeostasis. This compensatory anti-inflammatory response syndrome (CARS) reverses the SIRS processes by reducing lymphocytes, decreasing cytokine response, and expressing specific cytokines that suppress tumor necrosis factor. It can be conceived, then that the immunosuppression associated with sepsis contributed to the termination of seizures in both patients. Investigators are still attempting to better understand CARS, in hopes of targeting therapies to better treat infections. These same therapies could be of benefit in effectively treating SRSE.

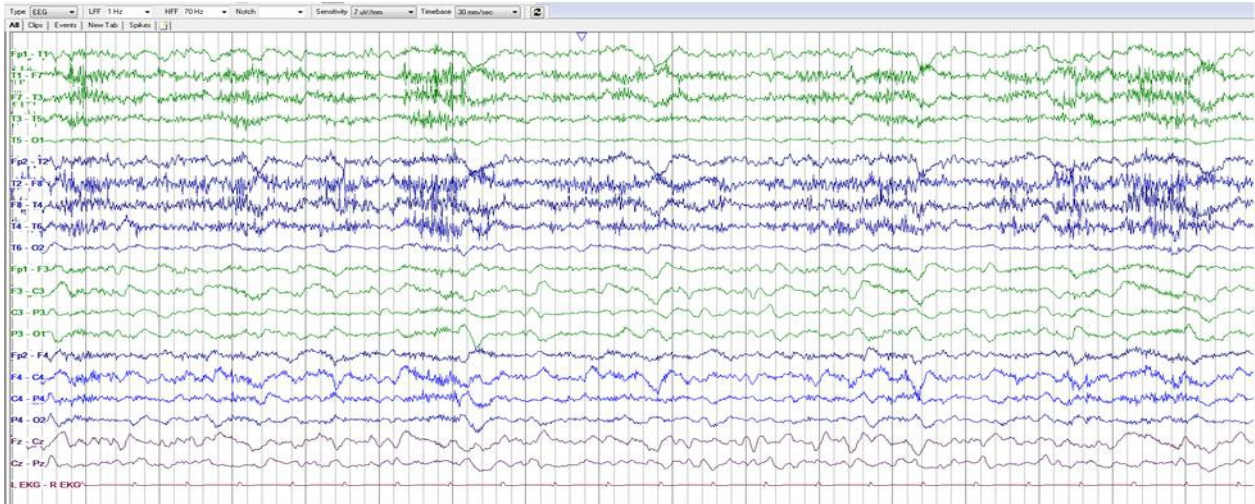
Further research should be conducted to investigate what aspects of cardiac arrest or sepsis could play a role in termination of SE. Although the authors are not recommending cardiac arrest or sepsis as a potential treatment for SE, exploration into specific mediators involved in these conditions and their relationship to SE could uncover therapeutic targets. Targeted therapies may demonstrate promise in effectively treating SRSE, thereby improving morbidity and mortality rates.

## Figures

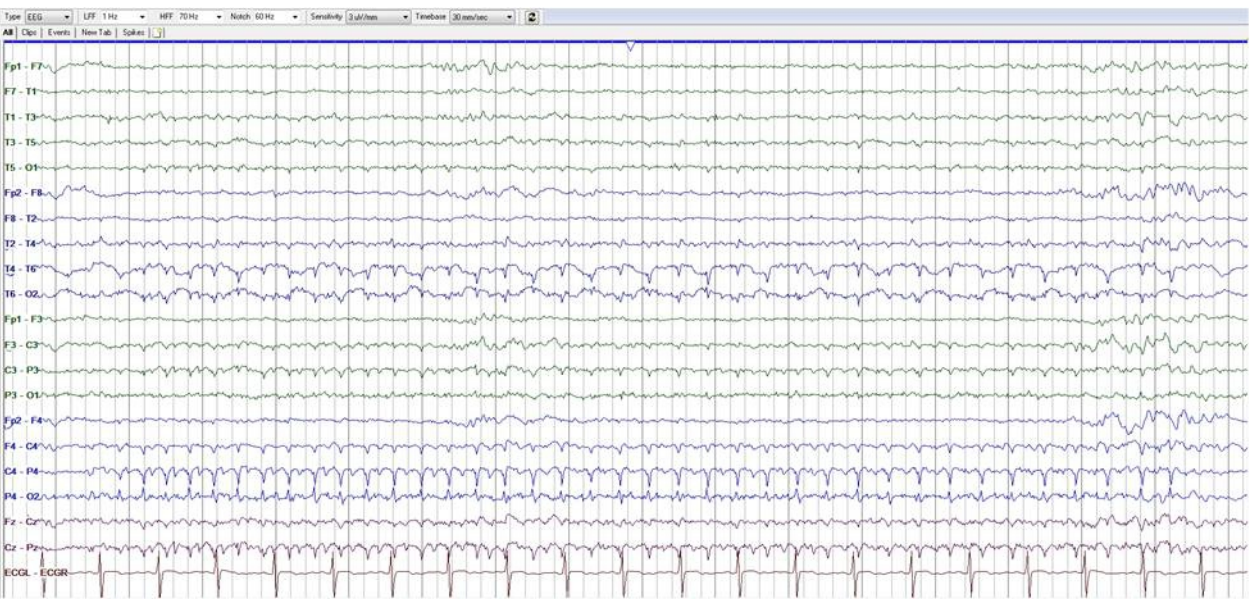

**Figure 1:** Pre-Arrest EEG 1. Seizures originating from left temporal lobe with secondary generalization

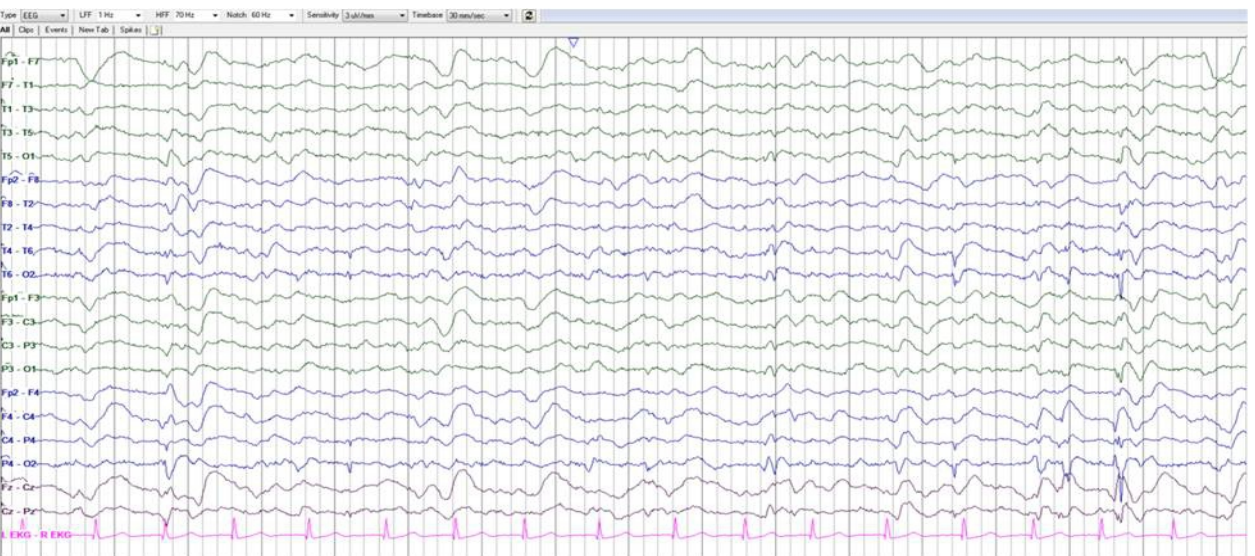




**Figure 2:** Post-Arrest EEG 1. Background of moderate diffuse slowing with generalized discharges with triphasic morphology.



**Figure 3:** Pre-Arrest EEG 2. Recurrent right posterior temporoparietal onset seizures.



**Figure 4:** Post-arrest EEG 2. Diffuse slowing with posterior right lateralized pseudoperiodic discharges without further seizures