

Recurrent pemphigoid gestationis is experienced by a woman in subsequent 3 pregnancies; an emotional impact on the patient seeking for permanent sterilization—A case report

Nishat Fatema*; Yaseer Muhammad Tareq Khan; Mahin Rahman

*Nishat Fatema

Department of Gynaecology& Obstetric, Ibri Regional Hospital, Ministry of Health, Sultanate of Oman

Abstract

Pemphigoid gestation is (PG) is a rare autoimmune bullous dermatosis of pregnancy. Incidence of PG is around 1:10,000 to 1:50,000 pregnancies. The accurate pathogenesis of PG is still not described well in literature. PG typically develops in the second and third trimester of pregnancy or immediate post partum flare up can also occur. Linear deposition of third component of compliment (C3) along the basement membrane in direct immunofluorescence test is a confirmatory diagnosis of PG. Systemic corticosteroids (CS) has been the first line treatment. There is high chance of recurrence of PG in subsequent pregnancies with extensive lesions. We report a case of a 34-year-old woman, G5P3Ab1 of recurrent PG in her successive three pregnancies with one post partum flare up. Her last pregnancy was complicated with extensive PG lesions from the 20-week gestation and had preterm delivery at 34 weeks gestation. Patient became emotionally disturbed due to relapse of PG in each pregnancy and sought permanent sterilization. For such cases of recurrent PG, reassuring and counseling is necessary regarding relapse of PG and its complications in subsequent pregnancies so that the patient can plan her future pregnancy, can be aware of the disease's course, and can obtain relief from psychological stress.

Keywords

pemphigoid gestationis; dermatosis; pregnancy; sterilization

Introduction

Pemphigoid gestation is (PG) is a rare autoimmune bullous skin disorder occurring during pregnancy. PG previously was termed as herpes gestationis because of its blistering appearance, though there is no relation of this disease to the herpes infection. Among bullous skin disease in pregnant women, PG is third most common condition [1].

The incidence of PG mentioned earlier in literature is around 1:10,000 to 1:50,000 pregnancies [2].

Common presentation of PG is severe pruritic urticarial skin lesions in the form of papules and plaques followed by formation of blisters and tensed vesicles, located on the abdomen, limbs and trunk. PG typically develops in the second and third trimester of pregnancy, and also immediate post partum flare up can occur [3,4].

The diagnostic criteria of PG includes clinical presentation, biopsy and histopathologic findings of subepidermal blistering process and the linear deposition of third component of complement (C3) along the basement membrane in direct immunofluorescence test, with deposition of immunoglobulin G around 25-30% cases [4,5].

Systemic corticosteroids (CS) have been the first line treatment. Steroid resistant cases are treated with intravenous immunoglobulin (IVIg) [6].

In most of the cases, it is self-limiting and resolves after delivery, but symptoms may persist or flare up during the postpartum period. In subsequent pregnancies, its symptoms become more serious. In multigravida the condition appears earlier in gestation than primigravida [3].

Women with PG may experience a high recurrence rate in subsequent pregnancies, may aggravated with menstruation, use of oral contraceptive pills and may require more aggressive immunosuppression [1,7].

Around 8% of successive pregnancies may skip the recurrence of PG though there is high chance of recurrence in subsequent pregnancies. There is evidence of relapse of PG during menstruation or oral contraceptive use in 25% of cases. Miscarriages may occur around 20% of patients, intra uterine growth restriction (IUGR) and premature delivery (20%) and skin lesions in neonate (10%) are also not uncommon due to PG [8,9].

We report a case of 34-year-old G5P3Ab1 of recurrent PG in her successive three pregnancies with post partum flare up once which resolves eight weeks after steroid therapy. Her current pregnancy was complicated with PPRM at 34 weeks gestation and the clinical presentation of PG was more extensive and earlier appearance than previous two pregnancies. Patient was emotionally upset and sought permanent sterilization to get rid of this condition. However, we performed bilateral tubal ligation in view of her previous history of three LSCS and the subsequent pregnancies in which the lesions of PG worsened and complicated her pregnancy course.

Such cases of recurrent PG need special attention and counseling regarding relapse of PG and its complications in subsequent pregnancies and use of appropriate contraception so that the patient can plan her future pregnancy and be aware of the disease, its recurrence, remission and complications in future pregnancies.

Case Presentation

Our reported case was a 34-year-old G5P3Ab1 woman who experienced the disease pemphigoid gestationis in three consecutive pregnancies. During her third pregnancy, she suffered the first attack of PG. At 24 weeks of gestation, she was presented to our ANC clinic with complaints of intense pruritic rash over extremities, trunk and abdomen with blisters and papules. Her first pregnancy ended as miscarriage, followed by a full-term live baby delivery by Cesarean section due to non-progress of labor in her second pregnancy. She had no history of significant medical or surgical comorbidities.

We referred her to dermatology for detailed examination and diagnosis. Punch biopsy was obtained from lesions of lower limb and sent for histopathology. Histopathology revealed that, in dermis perivascular lymphocytic and histocytic infiltrate with eosinophils and the features consistent with PG,

diagnosis confirmed by direct immunofluorescence test. She was treated with prednisone 15 mg daily and gradually tapered till 10 mg. At term she delivered a live baby by cesarean section due to ante partum hemorrhage. After delivery rashes flared up, managed with tab prednisolone 20 mg daily. The lesions completely resolved two months after onset. Prednisone dose was tapered gradually and discontinued.

Two years later, she had her fourth pregnancy. Again at 24 weeks of gestation, she developed rashes on abdomen and limbs same as her previous pregnancy and the lesions controlled with oral prednisolone.

At 38 weeks of gestation, an elective cesarean section(C/S) performed for her in view of previous two cesarean delivery. This time she didn't suffer from post partum PG flare up and lesions resolves completely within two weeks after delivery.

Four years later during her last (5th) pregnancy, rashes appeared at 20 weeks gestation with more active lesions. Treatment started with prednisolone and no new lesions developed after treatment initiation. But the patient became depressed psychologically as during each of her pregnancies she suffered a lot. During her antenatal visit, she requested permanent sterilization to avoid future pregnancies as well as the disease. Unfortunately, at 34 weeks gestation she got admitted with preterm premature rupture of membrane (PPROM). Clinically PPRM was diagnosed, and we kept her admitted in the hospital for dexamethasone and antibiotic coverage. Her USG fetal biophysical profile was good with estimated fetal weight was 2.00 kg. An elective cesarean section done in view of PPRM and previous history of three C/S. Simultaneously, bilateral tubal ligation was done due to previous three C/S and with each pregnancy the PG lesions had worsened, complicating the pregnancy, causing increased morbidity of the patient and her baby, and also affecting psychological status of the patient. She delivered a preterm alive mild IUGR infant with weight 1.9 Kg. Postpartum, she had no flare up of PG and lesions completely resolved within two weeks of delivery. Fortunately, all her babies were born healthy and asymptomatic without any cutaneous lesions.

Discussion

Pemphigoid gestation is a rare autoimmune bullous dermatosis of pregnancy. The accurate pathogenesis of PG is still not described well in literature [6].

It is hypothesized that PG arise from maternal pathologic IgG initiated by paternal HLA antigens that found in the placenta. Circulating IgG autoantibodies likely react against hemidesmosomal components and transmembrane proteins of the epidermal basal cells. Through the classical pathway, it activates a complement system that aggregate eosinophils to the site where they degranulate, which causes damage to the dermal and epidermal connection causes blisters formation [10,11].

Typically, PG occurs during second and third trimester of pregnancy or sometimes in the immediate postpartum period. The lesions begin on the abdomen involving umbilicus and spread over trunk and extend to other flexural area with intense pruritus. The mucous membrane, face, palm of the hands and dorsum of the feet are commonly spared from disease involvement [7].

Our patient presented in her third pregnancy at 24 weeks gestation with typical clinical presentation of PG which was characterized by urticarial plaques and blisters over trunk, abdomen and extremities. No lesions were observed in mucosal surfaces.

In a retrospective cohort study of 32 patients with PG, F. Al-Saif et. al reported that primigravidae are more susceptible to get first attack of PG in comparison to multigravidae. They mentioned only two patients with PG had their first attack at ninth and 11th pregnancy late in their reproductive life, and which was not discussed prior in the literature [1].

In contrast, our patient experienced her first attack in her third pregnancy and followed by recurrence in subsequent next two pregnancies.

Pathogenesis of flare of PG during postpartum period, during menstruation and following oral contraceptive use is thought to be due to estrogen and progesterone. Lesions of PG usually resolve gradually in postpartum period. Exacerbation of disease process has been reported in literature from two weeks up to 12 years postpartum [7,8].

Our patient had one postpartum flare with new blisters formation and resolved after eight weeks of delivery, but there was no exacerbation seen during menstruation. Regarding contraception, she had no history of taking contraceptive pills or other contraceptive methods.

Castro et. al and colleagues in a report of 10 cases of PG mentioned about three cases in which premenstrual flare of disease occurred [7].

The differential diagnosis includes bullous pemphigoid, drug reaction, allergic contact dermatitis and pruritic urticarial papules and pustules of pregnancy (PUPP) [11].

In relation to the diagnosis of PG, a biopsy from the effected site for histopathology is helpful, but the direct immunofluorescence studies (DIF) is the confirmatory test to distinguish PG from other dermatological disorders of pregnancy. In DIF, Linear deposition of compliment 3(C3) along the basement-membrane zone in perilesional skin is confirmatory diagnosis of PG [12].

ELISA can be done to monitor autoantibody serum levels of bullous pemphigoid antigen 2 antibodies (BP180) in patients who refuse a skin biopsy or in whom a biopsy cannot be done. But DIF is the gold standard diagnostic tool for PG and in general practice and routine diagnosis setting [7,11].

In case of our patient, initially a skin biopsy for histopathology done, which revealed in dermis perivascular lymphocytic and histocytic infiltration with eosinophils and the features consistent with PG. The diagnosis was confirmed by linear deposition of C3 in DIF test.

The aim of treatment for PG is to make the patient free from pruritic symptoms and to reduce and prevent eruption of blisters. Oral systemic corticosteroid (prednisone, 0.5-1.0 mg/kg/d) is the drug of choice for management of moderate to severe PG but in mild cases topical glucocorticoid and antihistamines are helpful. Following the course of treatment, prednisolone can be tapered gradually to a maintenance dose but increasing the dose at peripartum period when the flare of the disease most often occurs may be necessary. For steroid-resistant and more severe cases plasmapheresis, cyclophosphamide, azathioprine, cyclosporine and dapsone are used. They can be considered a last resort of treatment due to their potential side effects. Refractory cases to conventional treatment can be treated with intravenous immunoglobulin with corticosteroids and azathioprine or dapsone [12,13].

There is one reported case by T. Nguyen et. al for recurrent PG; they treated the patient with I/V Ig monotherapy. They did not observe any adverse maternal and neonatal outcome and PG was improved

within four weeks after initiation of Ig therapy [6].

Upon diagnosis of PG for our patient (first diagnosis during third pregnancy), we started treatment with oral systemic prednisolone. Initial dose was 15 mg and tapered until 10 mg and PG was controlled in her whole antenatal course. Two days after delivery, however, she had flare up of the disease, so the prednisolone dose was increased to 20 mg daily. About eight weeks was required for complete resolution of lesions, and then the prednisolone dose was tapered and discontinued.

The subsequent two pregnancies also were managed by prednisolone, and fortunately there was no further exacerbation of the disease in postpartum period.

The risk of recurrence of PG is increased in subsequent pregnancies with an earlier appearance and more flare of lesions than the previous pregnancy [1,14].

Our case was not an exception; in her third and fourth pregnancy, PG appeared at 24 weeks gestation, but for the fifth pregnancy she developed PG lesions at 20-weeks gestation with more extensive lesions.

Regarding neonatal outcome of patients with PG, newborns are a greater risk of adverse outcomes like small for gestation (20%), preterm delivery (20%), and placental insufficiency reported by F. Al-Saif et. al while investigating 32 cases with PG. Around 10% of infants may experience transient pruritic vesicular skin lesions [1,6].

In relation to this, our patient's three babies were delivered at full-term gestation without any complications, but during her last pregnancy she delivered a preterm and a mildly small for gestation live baby that we can be labeled as the consequence of PG complications, but the baby didn't acquire any skin lesions.

Deleterious clinical presentation of PG during pregnancy may affect psychologically the patient and as well as her family. For this reason, reassuring and detailed counseling is required. This includes a proper explanation of the nature and course of the disease, drug adverse effects, neonatal complications, recurrence and complications in future pregnancies. Patients with PG should be informed to avoid hormonal contraception that may play role in flare of the disease process [13,15].

Conclusion

The issues regarding the counseling and reassuring of patients with recurrent PG was not widely discussed in literature previously. Upon confirm diagnosis of PG appropriate counseling may help the patient to understand the disease course of PG, its recurrence and effects on subsequent pregnancies, so that they can plan their future pregnancy and can choose the contraceptive methods other than the hormonal contraception and obtain relief from psychological stress.

Figures

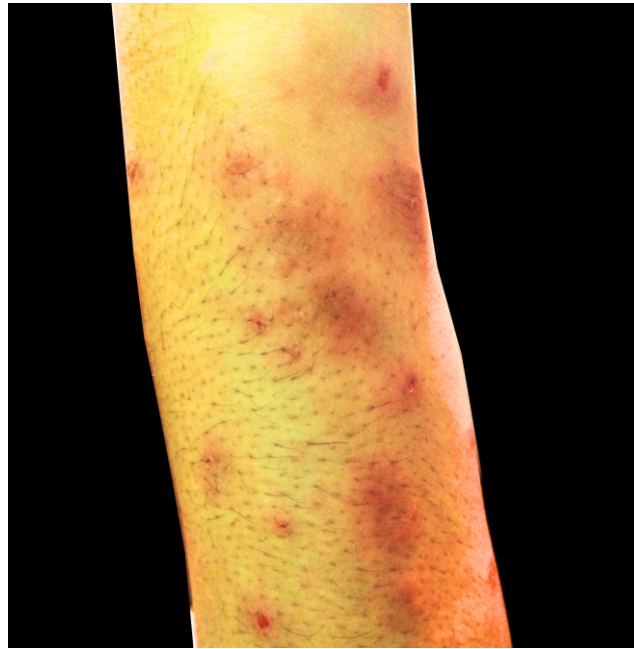

Figure 1: pruritic lesion of PG over arm

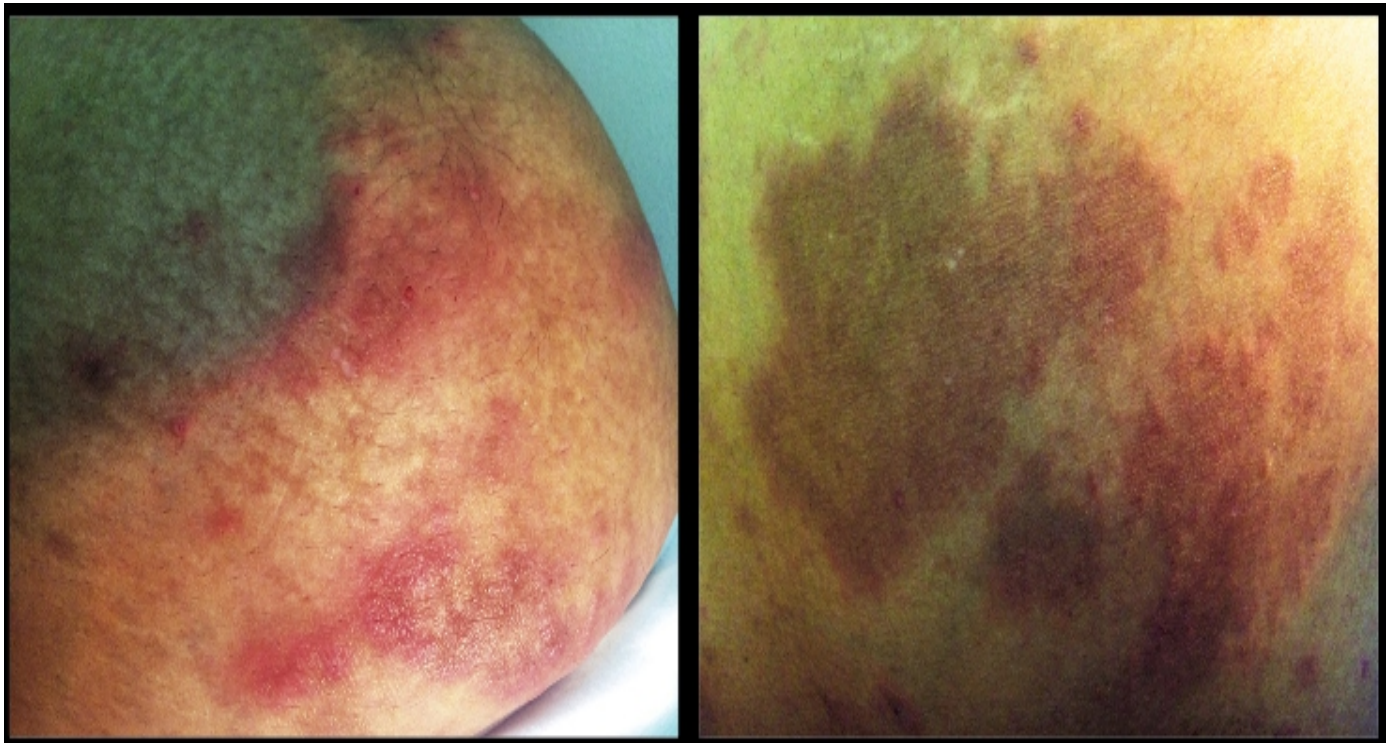


Figure 2: healed lesion of PG over abdomen

Tables

Table 1: Obstetric outcomes and PG related data of the patient

Patient's data	1 st pregnancy 2004	2 nd pregnancy 2005	3 rd pregnancy 2009	4 th pregnancy 2011	5 th pregnancy 2016
Gestational age 1 st presented with PG	-	-	24	24	20
Treatment	-	-	Prednisolone	Prednisolone	Prednisolone
Pregnancy complication	Miscarriage	-	-	-	PPROM ^a at 33 weeks
Gestation at time of delivery (week)	-	40	40+4	38	34
Mode of delivery	-	LSCS ^b	LSCS	LSCS	LSCS+BTL
Indication for LSCS	-	Non progress of labour	APH ^c	Elective inview of 2 previous LSCS	PPROM at 34 weeks
Neonatal outcome	-	Term alive	Term alive	Term alive	Preterm alive
Baby weight	-	3	3.1	2.9	1.9(SGA ^d)
Post partum flare up	-	-	Yes	-	-
Hospital stay	-	6	6	5	5
Remission (weeks)	-	-	8	2	2

^aPPROM-Preterm premature rupture of membrane

^bLSCS-Lower uterine segment cesarean section

^cAPH-Antepartum haemorrhage

^dSmall for gestation

References

- Al-Saif F, Elisa A, Al-Homidy A, Al-Ageel A, Al-Mubarak M. Retrospective analysis of pemphigoid gestationis in 32 Saudi patients – Clinicopathological features and a literature review. J Reprod Immunol [Internet]. 2016 Aug ;116:42–5.
- Argueta EE, Tschen JA. What is your diagnosis? pemphigoid gestationis (herpes gestationis). Cutis [Internet]. 2015 May;95(5):268, 270.
- Tani N, Kimura Y, Koga H, Kawakami T, Ohata C, Ishii N, et al. Clinical and immunological profiles of 25 patients with pemphigoid gestationis. Br J Dermatol [Internet]. 2015 Jan;172(1):120–9.
- Cabral R, Teixeira V, Brinca A, Fernandes B, Reis JP. Case for diagnosis. An Bras Dermatol [Internet]. 2014 Jan ;89(1):167–8.
- Engineer L, Bhol K, Ahmed AR, Dupont C, Tillman W, Peer L, et al. Pemphigoid gestationis: A review. Am J Obstet Gynecol. 2000 Aug;183(2):483–91.
- Nguyen T, Alraqum E, Razzaque Ahmed A. Positive clinical outcome with IVIg as monotherapy in recurrent pemphigoid gestationis. Int Immunopharmacol [Internet]. 2015 May;26(1):1–3.
- Castro LA, Lundell RB, Krause PK, Gibson LE. Clinical experience in pemphigoid gestationis: Report of 10 cases. J Am Acad Dermatol [Internet]. 2006 Nov;55(5):823–8.