

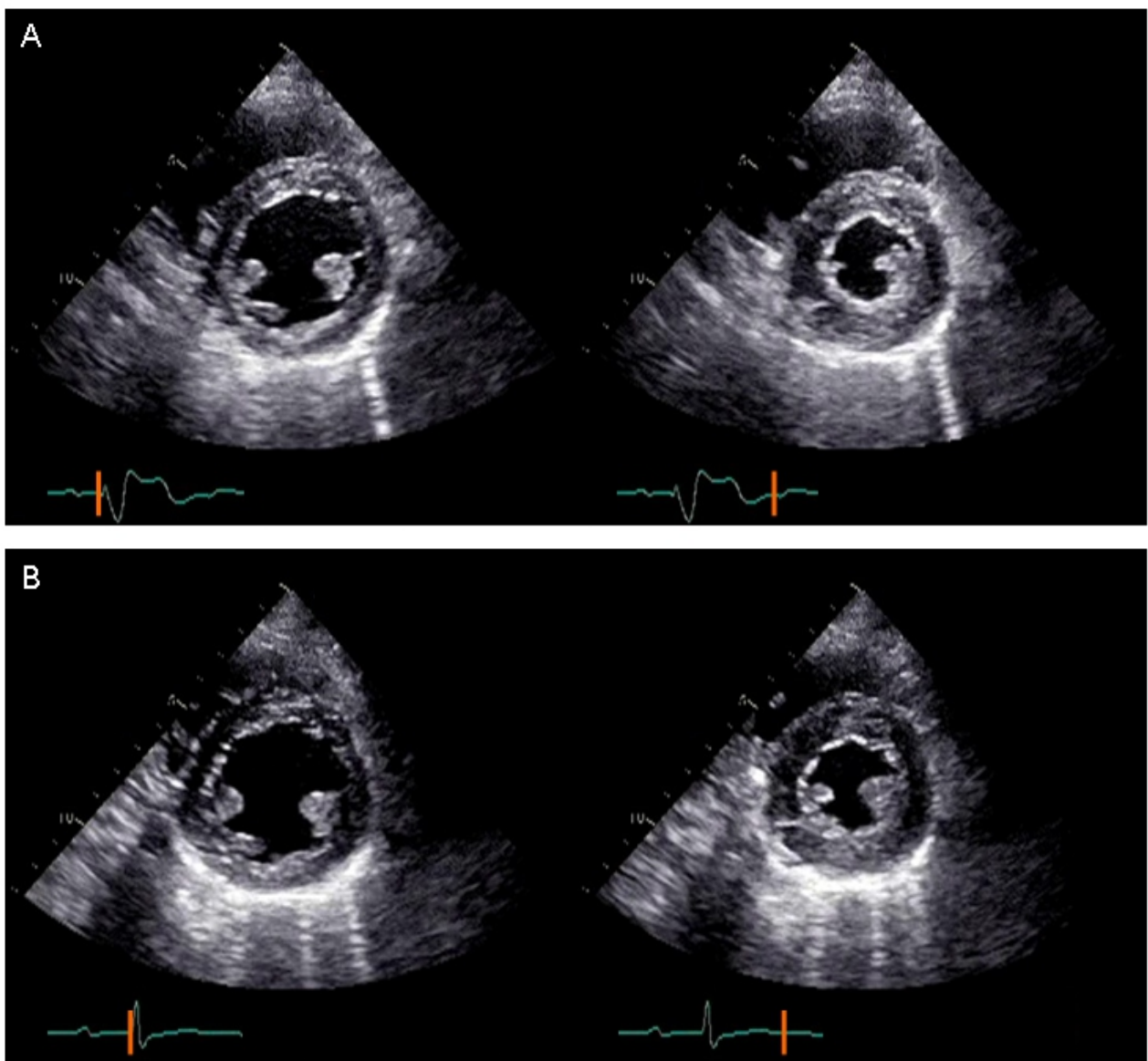
## Ventricular fusion beat on echocardiography

Ayumi Shirota, MD\*; Tatsuya Kawasaki, MD, PhD; Michiyo Yamano, MD; Tadaaki Kamitani, MD, PhD; Satoaki Matoba MD, PhD

**Ayumi Shirota, MD**

Department of Cardiology, Matsushita Memorial Hospital, Osaka, Japan

### Clinical Image



**Figure 1:** Short-axis echocardiographic images of the left ventricle show good contractility without dyssynchrony regardless of paced wide QRS complex on monitor (Panel A). Panel B shows longer PQ intervals and narrower QRS durations than in Panel A.