

An interesting change in a focal choroidal excavation after intravitreal ranibizumab treatment for choroidal neovascularization: conversion from non-conforming to the conforming type

Abdullah Ozkaya, MD*; Gurkan Erdogan, MD; Irfan Perente, MD; Muhittin Taskapili, MD

*Abdullah Ozkaya, MD

Beyoglu Eye Research and Training Hospital, Beyoglu, İstanbul, Turkey

Abstract

Focal choroidal excavation is a relatively new described chorioretinal abnormality which was showed to be associated with several macular diseases and had two subtypes. This case report summarizes the treatment outcomes of a 61-year-old caucasian male who showed a choroidal neovascularization (CNV) secondary to focal choroidal excavation (FCE) in his left eye and treated successfully with intravitreal ranibizumab. Also the lesion was a non-conforming FCE at beginning and also at the time when CNV was detected, then 16 months after the first detection of the CNV the lesion converted to a conforming type.

Keywords

Choroidal neovascularization; focal choroidal excavation; ranibizumab

Abbreviations

FCE: Focal choroidal excavation; OCT: optical coherence tomography; RPE: retinal pigment epithelium; BCVA: best corrected visual acuity; CNV: choroidal neovascularization; CSC: central serous chorioretinopathy

Introduction

Focal choroidal excavation is first described by Jampol et al in 2006 via OCT [1]. At that time the resolution of the OCT machines was not as good as the new devices we use today therefore, this lesion was not able to be analyzed in detail [2]. After the introduction of spectral domain and swept source OCT devices, it was hypothesized that FCE occurred secondary to a focal choroidal scarring process which pulled the RPE towards to the choroid [2]. The choroidal scar was shown via OCT [2]. Focal choroidal excavation is also categorized into two types which are conforming and non-conforming types [3]. If the outer retinal layers conform to RPE the lesion is described as a conforming FCE, if not it is described as a non-conforming one [3]. In the literature there is a little evidence about the progression of choroidal excavations [2,4]. Some transitions from one type to another are reported [2]. We aimed to report the treatment outcomes of a patient with choroidal neovascularization secondary to FCE who showed a transition from non-conforming type to conforming type after intravitreal ranibizumab treatment.

Case Report

A 61-year-old caucasian male admitted with the complaint of decreased visual acuity in both eyes in May 2010. He had a history of diabetes since two years. On ocular examination, best corrected BCVA was 20/32 in the right eye and 20/32 in the left eye. The patient had a mild myopia; the refractive error was -2.5 diopters in both eyes. Slit lamp examination of the anterior segment showed pseudoexfoliation syndrome in both eyes. Intraocular pressure was 24 mmHg and 24 mmHg in the right and left eye, respectively. As intraocular pressure was high in both eyes, the patient was evaluated in regard to glaucoma; the pachymetry was 599 microns and 593 microns in the right and left eye, respectively. Visual field test and optic head OCT were in normal limits. Therefore, the patient was diagnosed as ocular hypertension and pseudoexfoliation syndrome. Fundus examination showed non-specific retinal pigment epithelial changes in both eyes. Macular OCT showed a non-conforming FCE in both eyes (Figure 1). Fluorescein angiography was not notable except the irregular punctuate transmission defects at the posterior pole in both eyes (Figure 1). The right eye remained stable for the next 5 years; neither ocular hypertension transformed to glaucoma, nor there had been any change in FCE. However, the patient came back with the complaint of visual decrease in the left eye in April 2013. The visual acuity was decreased to 20/63. The fundus evaluation did not reveal a new additional finding, but OCT scan showed shallow two RPE detachments adjacent to the choroidal excavation (Figure 2). Also fluorescein angiography showed two granular hyperfluorescence areas which were correspondence to the shallow RPE detachments in the OCT below the previous transmission defect area (Figure 2). At this time point although there were obvious signs of an occult CNV in the right eye, we overlooked the clinical picture and did not suggest any treatment. And eventually, in December 2013, OCT showed a prominent subretinal fluid around the choroidal excavation then we realized that this fluid was secondary to a newly formed CNV (Figure 3). So, 3 consecutive monthly 0.5 mg/0.05 ml intravitreal ranibizumab injections were performed. After the injections, in April 2014 the visual acuity increased to 20/50 and subretinal fluid regressed significantly (Figure 3). In the follow-up period three additional ranibizumab injections were performed because of recurrence of subretinal fluid in May, July and October 2014. In April 2015 a significant change was detected in the base of the choroidal excavation (Figure 3). It transformed to conforming subtype, the previous optically empty space was filled with the outer layers of retina. The patient did not require any additional injections for the previous 17 months and was stable in March 2016, the visual acuity was still 20/50, and OCT was fluid free (Figure 3).

Discussion

Focal choroidal excavation was reported to be associated with many macular diseases such as CNV, CSC and Best vitelliform macular dystrophy etc [2-5]. The etiology and pathophysiology of FCE were not fully understood yet [2-4]. Some authors hypothesized that FCE might be a focal faulty differentiation of chorioretina as a developmental disorder, on the opposite, some of them suggested that FCE might occur because of a focal choroidal scar as an acquired disorder [2,4]. Also there is a little data about the types of FCE. Two distinctive types were described in previous studies [3]. In a study by Liu et al (2015) in which 37 eyes were included, it was reported that 46.9% of the eyes showed a non-conforming type and unilaterality was reported as 84.4% [6]. Also they reported that 21.9% of the FCE patients showed CNV and 12.5% showed CSC. In the study they reported a literature review and showed that the disease

affected both genders equally, and most of the FCE patients were myopic. The follow-up period for the study was from 2 months to 43 months; however, they did not report any transformation from one type to another [6]. In another study by Kim et al [2], 12 eyes were evaluated and they reported that in 11 of the 12 eyes showed a conforming FCE. Double FCEs were shown in two eyes in the study and the associated diseases were reported as age-related macular degeneration, polypoidal choroidal vasculopathy, CSC, and epiretinal membrane. Interestingly, in a CSC patient, they reported a conversion like in our case, in the reported eye converted from a non-conforming FCE to a conforming one. In the current report we reported the treatment outcomes of FCE patient who developed a CNV during follow up and who showed a conversion in the lesion type after treatment.

Figures

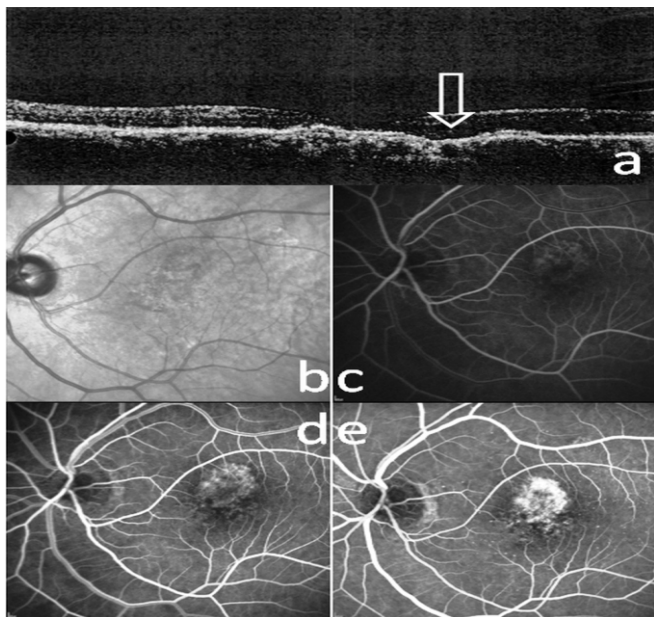


Figure 1: a) Optical coherence tomography scan of the left eye in May 2010 shows a non-conforming focal choroidal excavation; b) infrared image; c,d,e) fluorescein angiography shows transmission defect at the fovea.

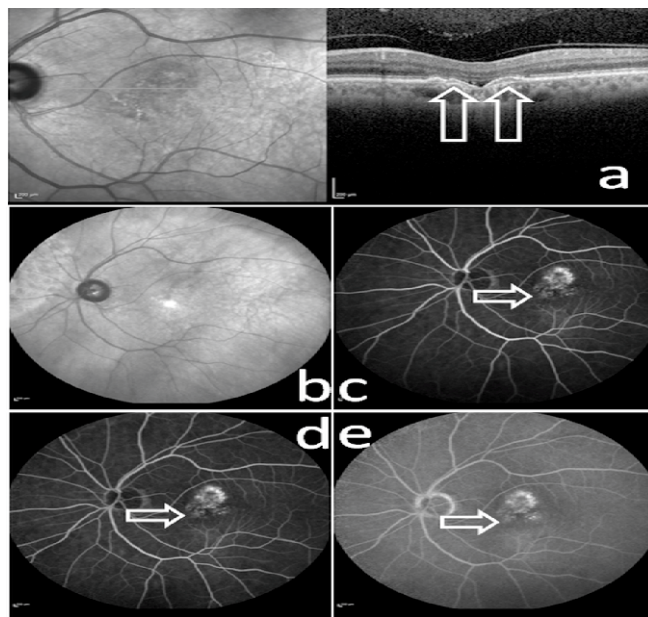


Figure 2: a) Optical coherence tomography scan of the left eye in April 2013; white arrows show two little retinal pigment epithelial detachments; b) infrared image; c,d,e) white arrows show the new hyperfluorescent areas in fluorescein angiography which represent occult choroidal neovascularization corresponding to the retinal pigment epithelial detachments in optical coherence tomography.

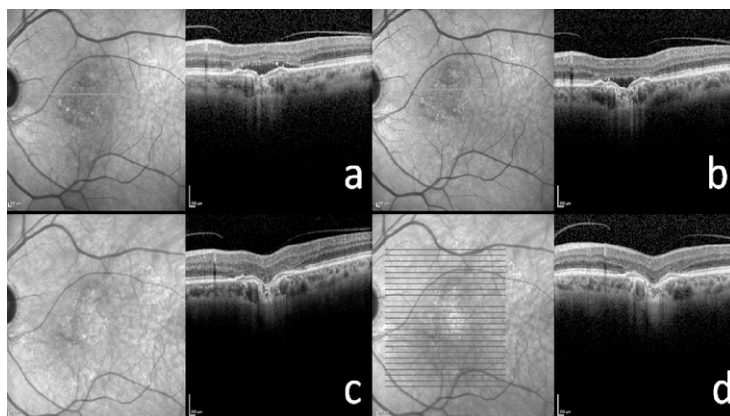


Figure 3: a) The optical coherence tomography scan in December 2013 shows a prominent subretinal fluid accumulation; b) in April 2014, after 3 intravitreal ranibizumab injections subretinal fluid nearly disappeared; c) in April 2015, the focal choroidal elevations converted to conforming type; d) the last follow-up visit in March 2016, macula was fluid free for the previous 17 months.