

Pseudomyxoma peritonei: A rare intra-abdominal malignancy

Jonathan Barney*; Jimmy Phan; James Ching

*Jonathan Barney

American University of the Caribbean School of Medicine, 880 SW 145th Avenue Suite #202, Pembroke Pines, FL 33027

Email: jonathanbarney87@gmail.com

Abstract

In this case report, we describe a 55-year-old female patient who presents with abdominal discomfort and distention in the context of a prior diagnosis of pseudomyxoma peritonei – a rare appendiceal epithelial tumor which produces copious amounts of mucus. This condition leads to ascites and mass effect, among other more serious complications. The case of this patient is discussed with clinical presentation, imaging, labs, and pathology included. Additionally, we provide an overview of the etiology, epidemiology, pathophysiology, complications, diagnosis, and prognosis of this condition.

Keywords

diagnosis; tumor; pathology; pathophysiology

Case Report

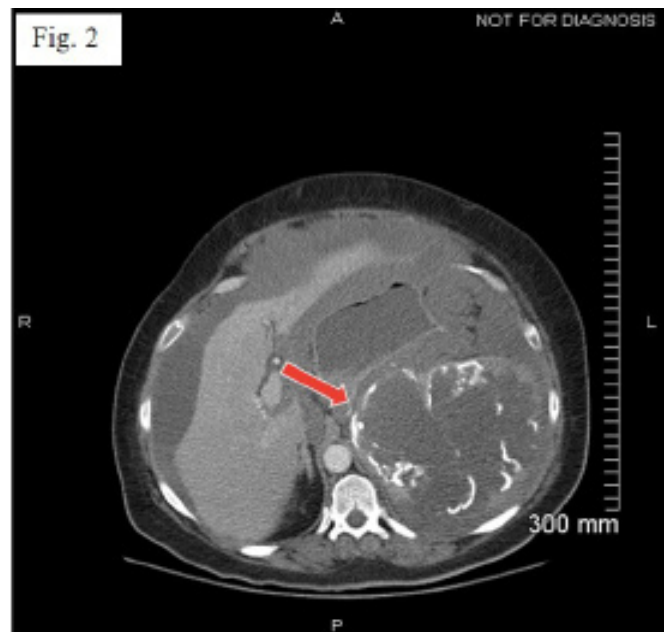
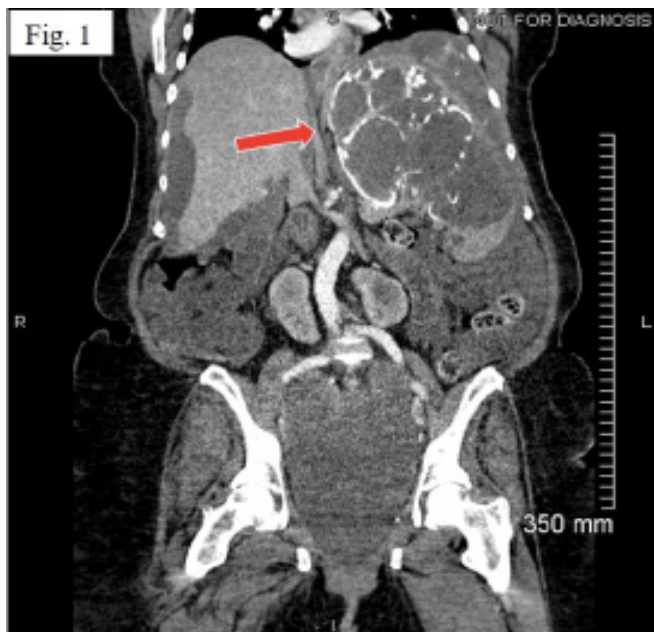The patient is a 55-year-old Caucasian female with a medical history significant for pseudomyxoma peritonei (PMP) first diagnosed in 2001, following a total abdominal hysterectomy and bilateral salpingo-oophorectomy (TAH/BSO) that was performed due to pelvic mass suspicious of malignancy. Pathology results of the specimen obtained at that time confirmed disseminated peritoneal adenomucinosis involving the ovaries and Fallopian tubes bilaterally, the serosa of the uterus, the appendix, and the greater omentum. The patient received six months of chemotherapy treatment with gemcitabine/cisplatin and was followed by gynecology at 6-month intervals with tumor marker monitoring following the therapy.

In 2010, the patient developed a ventral hernia at the site of the abdominal incision that had been made during her previous TAH/BSO. The hernia was surgically repaired with mesh placement. Her post-op course was complicated by infection of the mesh, with formation of a draining fistulous tract. The patient was treated for this complication with incision and drainage and antibiotic administration via peripherally inserted central catheter (PICC) line. She developed an abdominal wall abscess at the site of infection, which was then treated with drainage by interventional radiology (IR). This provided relief, and inpatient

treatment was not required again until 2012.

In 2012, the patient had recurrence of the abdominal wall abscess presenting with fever, periumbilical erythema and induration. The treatment this time was essentially the same as in the previous instance, and included drainage by IR, and IV antibiotics via PICC line as an outpatient. Within a few days of the antibiotic regimen being completed, the patient's symptoms of abscess recurred again. IR drainage and IV antibiotics were again initiated, but by this time it was clear this was not likely to be curative. Surgery was consulted, and the decision was made to remove the infected mesh from the abdominal wall.

During the operation to remove the mesh, the surgeon noted that the PMP had completely engulfed the left upper quadrant of the abdomen and was intertwined with the small bowel; findings consistent with the CT obtained prior to the operation (Figure 1,2,3).



CT Abdomen and Pelvis without contrast

Indication: Pseudomyxoma peritonei, rule out abdominal abscess

Findings: There is a new finding of abscess cavity measuring 16.1 cm X 12.4 cm in size within the left lower quadrant in the abdominal wall, which was not seen on the previous study. There is a well defined rounded cystic mass or fluid collection in the lower abdominal wall to the right, and behind the abscess cavity. Abnormal air is noted within the large abscess cavity within the abdominal wall. There is soft tissue edema of the abdominal wall. There are multiple calcified and noncalcified masses in the peritoneal cavity. Ascites is noted. There are horseshoe kidneys. Hydronephrosis of the kidneys is noted.

Impression:

1. New findings of a large 16.1 cm X 12.4 cm abscess cavity within the left lower quadrant of the abdominal wall, which was not seen on the previous study.
2. A well defined cystic structure measuring 6.2 cm X 8 cm, which is unchanged since the previous study.
3. Multiple masses within the peritoneal cavity. Some of the masses are calcified.
4. Abdominal ascites.
5. Horseshoe kidneys with hydronephrosis.
6. Foley catheter within the urinary bladder.

Pathology Report

SPECIMEN A. CLINICAL FISTULA WITH MESH, FISTULECTOMY:

- Focal areas of lake of mucin with mucinous epithelium surrounded by a foreign body, multinucleated giant cell reaction.
- Findings consistent with the clinical impression of pseudomyxoma peritonei
- Focal areas of granulation tissue with marked to mixed inflammation.

SPECIMEN B. TUMOR, ABDOMEN, DEBULKING:

- Sheets of mucin with mucinous epithelium consistent with low grade mucinous neoplasm (see comment)
- Findings consistent with the clinical impression of pseudomyxoma peritonei.

COMMENT: Focal areas with increased mitotic activity may suggest a transformation to a mucinous carcinoma. Clibal and radiologic correlation and followup is strongly recommended.

The surgeon performed an exploratory laparotomy with removal of the infected abdominal wall mesh, debulking of the PMP, and closure of the incisional hernia with bilateral abdominal wall full thickness fasciocutaneous advancement flaps. Analysis of the imaging, pathology of excised mass specimen (Figure 4), and surgical findings in the context of the clinical picture confirmed the continued presence of pseudomyxoma peritonei.

Post-op, the patient was admitted to the Definitive Observation Unit (DOU) for intravenous antibiotics, parenteral nutrition support, wound drainage, and close monitoring. Her hospital course was uneventful, and she was discharged home. Post-discharge, the patient suffered from wound dehiscence and sepsis due to central line infection requiring re-admission to the hospital for another course of intravenous antibiotics and acute management. The patient was eventually able to be discharged home and did not require inpatient treatment again until 2014.

In 2014, the patient was brought to the emergency department complaining of dizziness, fatigue, severe abdominal distention, cramping, and painful aphthous ulcers that made eating and drinking difficult. Additionally, the wound that had been the site of recurrent infection began draining copious amounts of feculent material and bloody discharge resulting in symptomatic anemia requiring admission. She was diagnosed as having advancement of the PMP with multiple organ involvement and chronically draining fistula. After discussing medical and surgical options with her medical team, the patient decided against aggressive treatment due to severity of her condition and poor prognosis. She was discharged to hospice care in July of 2014 and passed away in October of the same year.

Discussion

Etiology

Pseudomyxoma peritonei (PMP) is a rare mucus-producing neoplasm that can originate from locations in both the gastrointestinal and genitourinary tracts. It most commonly rises from a perforated appendiceal epithelial tumor. Though the exact cause is not well understood, there may be association with K-RAS mutations. A study was performed on identical twins, where both developed appendiceal mucinous adenomas but only one went on to develop PMP (in addition to the appendiceal tumor). In the twin that

developed PMP, the authors discovered identical K-RAS mutations in both the PMP tumor and appendiceal tumor; while the twin that only developed the adenoma had a different K-RAS mutation [1]. While primary appendiceal epithelial lesions in general occur infrequently, only about one third of those progress to become PMP.

Epidemiology

PMP is an incredibly rare condition, occurring with an incidence of only 1 to 2 per million, per year [2]. According to the National Organization for Rare Disorders (NORD), PMP occurs with equal frequency between men and women, with an average age of onset of 48 years. Furthermore, NORD comments on the oft stated misconception that this occurs more frequently in woman, stating that this is only reported because some ovarian tumors are mistakenly identified as pseudomyxoma ovarii [3].

Pathophysiology

The pathophysiology of PMP involves a sequence of events. First, the tumor cells of the mucinous epithelium of the appendix begin producing mucus, forming an adenoma that occludes the appendiceal lumen. As mucus production continues, the appendix essentially becomes a progressively distending mucocele [2]. Eventually the appendix ruptures, spilling its mucinous contents into the peritoneal cavity. The tumor cells easily move through the peritoneal fluid within the mucus, as they lack adhesion molecules. This is a distinctive feature of PMP known as “redistribution”; i.e. the accumulation pattern at diffuse sites throughout the abdomen and pelvis as the result of peritoneal migration [4]. The location of these implantations is often in the small lymphatic systems of gravity dependent areas such as the right paracolic gutter (where peritoneal fluid is reabsorbed) as well as the rectovesical pouch and pouch of Douglas [5]. Once implanted, these tumor cells will continue making mucus, leading to the prominent mucinous ascites sometimes referred to sardonically as “jelly belly” [6].

Complications

The natural course of this condition is continued mucus production and resultant accumulation of mucinous ascites. Eventually this will fill the peritoneal cavity and extend to the diaphragm. The accumulation can be so copious as to engulf the stomach and spleen [2]. If left unchecked it will end with starvation from obstructive compression. Other complications include perforated bowel, abscess, fistula formation, and thromboembolism [2].

Diagnosis

Diagnosis of PMP is accomplished by obtaining imaging studies, circulating tumor markers, and histopathology. CT scan of the chest/abdomen/pelvis is the imaging study of choice and may show scalloping of the liver and spleen due to mucin accumulation [7]. MRI with contrast can be helpful in localizing the tumor and evaluating the bowel, while PET/CT can be employed to scan for extra-abdominal involvement. Serum tumor markers CEA and CA 19-9 are typically elevated in PMP, and though not commonly used for diagnosis (as their utility in this regard is uncertain), they are useful for the purposes

of prognosis and follow-up monitoring post-treatment [8]. Additionally, CA-125 will be elevated if there is ovarian involvement. The definitive diagnosis is based on histopathology findings. The preferred sample for examination is a surgical specimen, as percutaneous image-guided biopsies can sometimes only yield acellular mucin. Upon evaluation of the specimen, findings indicative of PMP are classified within one of the following two categories: disseminated peritoneal adenomucinosis (DPAM) and peritoneal mucinous carcinomatosis (PMCA). DPAM specimens are peritoneal lesions with abundant extracellular mucin and focally proliferative mucinous epithelium without a large degree of atypia or mitotic activity. Specimens demonstrating more abundant mucinous epithelium with cytologic and structural features of carcinoma are classified as PMCA [9]. The specimens are then graded as either low or high. Low grade PMP is that demonstrating non-stratified simple cuboidal epithelium, unremarkable cytology, and mucin pools with low cellularity. High grade PMP is significant for signet ring morphology, severe cytologic atypia, and mucin pools with high cellularity [10,11]. Concerning histopathology, it is important to note that other pathologies of the abdomen (e.g. colonic mucinous neoplasms) can mimic features seen in PMP.

Differential Diagnoses

- Ascites from another origin (cirrhosis, CHF)
- Ruptured mucinous cystadenomas of appendix or ovary
- Endometriosis with myxoid change
- Ruptured viscus with mucus extravasation
- Soft tissue neoplasms with myxoid changes

Treatment

The optimal treatment for PMP is a combination of surgery and chemotherapy. The surgery is known as cytoreductive surgery (CRS), in which the goal is complete excision of the tumor, combined with hyperthermic intra-peritoneal chemotherapy (HIPEC). This operation can be extremely involved, lasting an average of 10 hours, and may entail resection of the diaphragm, bowel, omentum, spleen, liver; and even hysterectomy and bilateral salpingo-oophorectomy in female patients [7].

Prognosis

The prognosis for patients with PMP varies based on histological findings. According to one study, following treatment by CRS/HIPEC the ten-year survival rate for those with low-grade tumors, aka disseminated peritoneal adenomucinosis (DPAM) was 63%, while the ten-year survival rate for patients with high grade tumors, e.g. peritoneal mucinous carcinomatosis (PMCA) was 40.1%; and in patients with high-grade tumors with signet ring cells the ten-year survival rate was 0% [12].

Conclusion

Pseudomyxoma peritonei is a rare abdominal malignancy which produces copious amounts of mucus, contributing to abdominal distention and ascites. This is consistent with the clinical presentation and chief complaint of our patient. PMP only affects between 1 and 2 per million, per year, and is a type of appendiceal epithelial lesion, most likely related to K-RAS mutations. The tumor cells produce mucus which occludes the appendiceal lumen, distending it until it ruptures, spilling the mucinous contents into the abdomen. This leads to implantations of functional mucus producing cells causing mucinous ascites, resulting in the discomfort, progressive distention, and engulfing mass, as seen in our patient. If left unchecked, this may result in obstruction, perforation, thromboembolism; and in our case, abscess and fistula formation. Diagnosis is made by combining clinical presentation with imaging findings, laboratory markers such as CEA and CA 19.9, and histopathologic findings. The prognosis for patients suffering from this condition depends on the specific type and grade of tumor. Optimal treatment for PMP is cytoreductive surgery and hyperthermic intra-peritoneal chemotherapy. Though rare, this is an important cause of abdominal malignancy for clinicians to consider in patients presenting with mass or ascites.

References

1. Shih IM, Yan H, Speyrer D, Shmookler BM, Sugarbaker PH, Ronnett BM. Molecular genetic analysis of appendiceal mucinous adenomas in identical twins, including one with pseudomyxoma peritonei. *Am J Surg Pathol.* 2001; 25:1095-1099.
2. Bevan KE, Mohamed F, Moran BJ. Pseudomyxoma peritonei. *World J Gastrointest Oncol.* 2010. 15; 2: 44-50.
3. Sugarbaker PH. Pseudomyxoma Peritonei. National Organization for Rare Disorders (NORD). 2018.
4. Sugarbaker PH. Pseudomyxoma peritonei. A cancer whose biology is characterized by a redistribution phenomenon. *Ann Surg.* 1994 Feb;219(2):109-11.
5. Sulkin TV, O'Neill H, Amin AI, Moran B. CT in pseudomyxoma peritonei: A review of 17 cases. *Clin Radiol.* 2002; 57: 608-613.
6. Yu B, Raj MS. Pseudomyxoma Peritonei. 2019.
7. Mittal R, Chandramohan A, Moran B. Pseudomyxoma peritonei: natural history and treatment. *Int J Hyperthermia.* 2017; 33: 511-519.
8. Ramaswamy V. Pathology of Mucinous Appendiceal Tumors and Pseudomyxoma Peritonei. *Indian J Surg Oncol.* 2016; 7: 258-67.
9. Ronnett BM, Zahn CM, Kurman RJ, Kass ME, Sugarbaker PH, Shmookler BM. Disseminated peritoneal adenomucinosis and peritoneal mucinous carcinomatosis. A clinicopathologic analysis of 109 cases with emphasis on distinguishing pathologic features, site of origin, prognosis, and relationship to «pseudomyxoma peritonei». *Am J Surg Pathol.* 1995; 19: 1390-1408.
10. Misdraji J. Appendiceal mucinous neoplasms: controversial issues. *Arch Pathol Lab Med.* 2010; 134: 864-870.
11. Yantiss RK, Shia J, Klimstra DS, Hahn HP, Odze RD, Misdraji J. Prognostic significance of localized extra-appendiceal mucin deposition in appendiceal mucinous neoplasms. *Am J Surg Pathol.* 2009; 33: 248-255.
12. Baratti D, Kusamura S, Milione M, Bruno F, Guaglio M, Deraco M. Validation of the Recent PSOGI Pathological Classification of Pseudomyxoma Peritonei in a Single-Center Series of 265 Patients Treated by Cytoreductive Surgery and Hyperthermic Intraperitoneal Chemotherapy. *Ann Surg Oncol.* 2018; 25: 404-413.